

CASE REPORT

Keratocystic Odontogenic Tumor—Endoscopic Removal: Review of Two Cases

¹Suhasini P Ravichandran, ²Hemanth Vamanshankar, ³Jyotirmay S Hegde, ⁴Sunil K Saxena

ABSTRACT

Odontogenic keratocysts (OKCs) have an incidence of 5.4 to 17% of all odontogenic cysts. These OKCs are more common in the mandible, with cysts in the maxilla having incidence of 31.3% only. In the maxilla, they most commonly occur in the canine region. The rarity of this case presentation is in the fact that only 1% of maxillary OKCs will show involvement of maxillary sinus, which was seen in both our patients. Historically, OKCs have been treated by open approaches like Caldwell Luc. We present two of our cases that were treated by endoscopic endonasal approach with review of literature.

Keywords: Endoscopic, Excision, Keratocystic odontogenic tumor.

How to cite this article: Ravichandran SP, Vamanshankar H, Hegde JS, Saxena SK. Keratocystic Odontogenic Tumor—Endoscopic Removal: Review of Two Cases. Clin Rhinol An Int J 2017;10(3):154-156.

Source of support: Nil

Conflict of interest: None

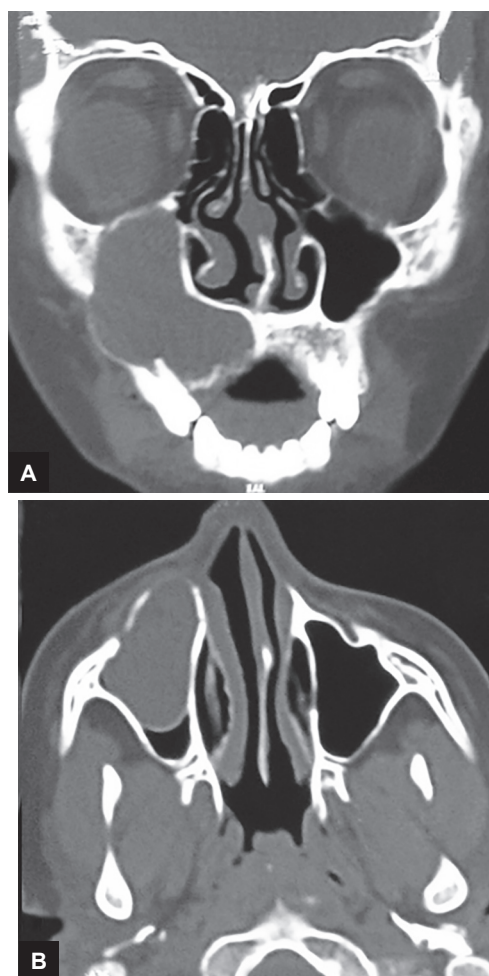
CASE REPORTS

Case 1

A 16-year-old male patient presented to us with complaints of a swelling over his right cheek, which was gradually progressing in size. There was no history of pain over the swelling; no trauma, no other nasal or eye complaints were noted. On examination, patient had slight tenderness over the right cheek area; there was no local rise in temperature. There was a diffuse swelling, firm in consistency, extending from the right infraorbital region to the upper lip, with obliteration of the nasofacial groove. No loss of sensation was noted over the cheek region. Examination of the oral cavity revealed effacement of the gingivolabial sulcus region corresponding to that of the first premolar upper tooth, on the right side,

with a firm swelling of 1 × 1 cm size. Examination of the nasal cavity was found to be normal.

In view of the external swelling being very diffuse and ill-defined, fine needle aspiration cytology could not be done. Diagnostic nasal endoscopy of the right nostril showed a medialized uncinate process, with no mass lesion in the middle meatus. We proceeded to do a contrast-enhanced computed tomography (CECT) scan of the nose and paranasal sinuses. This showed a well-defined cystic lesion within the right maxillary sinus, with the apex over the 1st premolar tooth. There was also thinning of the superior, anterolateral and inferior walls of the maxillary sinus (Fig. 1).



Figs 1A and B: Coronal (A) and axial (B) images of CECT scan showing a well-defined cystic lesion within the right maxillary sinus, with the apex over the first premolar tooth and corresponding wall thinning

¹Junior Resident, ²Senior Resident, ³Assistant Professor
⁴Professor and Head

¹⁻⁴Department of ENT, Jawaharlal Institute of Postgraduate Medical Education & Research, Puducherry, India

Corresponding Author: Hemanth Vamanshankar, Senior Resident, Department of ENT, Jawaharlal Institute of Postgraduate Medical Education & Research, Puducherry, India
Phone: +914132296191, e-mail: vhemanth2000@yahoo.com

The patient was planned for an endoscopic endonasal excision of the right maxillary cyst under general anesthesia. Anterior 1 cm of the right inferior turbinate was removed in order to gain access to the anterior aspect of the lateral wall using coblator. The maxillary sinus was entered from the anteroinferior aspect. The cyst was noted filling the maxillary sinus. The cyst wall was decompressed. It revealed a straw-colored fluid from within. Dissection of the cyst was done from all the walls. Inferomedially, the cyst was dissected off the inferior aspect of hard palate (Fig. 2). Thinning was noted over the superior and anterolateral walls of the sinus. The apex of the first and second upper right premolars was seen in the floor of the maxillary sinus. The cyst was excised *in toto*. The two premolar teeth were removed. A wide middle meatal antrostomy was then created. The sinus was packed with ribbon gauze soaked in 2% acriflavine solution. Pack removal was done on the second postoperative day. The patient had an uneventful recovery.

Case 2

A 40-year-old male patient presented to us with a swelling in the oral cavity since the past 3 years, which was progressively increasing in size. This was associated with pain over the right cheek since 1 year. There was no history of trauma or tooth extractions. No nasal or eye symptoms were present. Examination revealed a non-tender, soft, fluctuant swelling in the periodontal region of the last upper molar. There was tenderness over the right canine fossa.

Diagnostic nasal endoscopy was found to be normal. Contrast-enhanced CT of the nose and paranasal sinuses showed a well-defined expansile, hypodense, nonenhancing lesion of 3.4 × 3.1 × 2.2 cm, surrounding the roots of the upper right second and third molar, with extension into

the maxillary antrum. There was air fluid level within maxillary sinus, with thinning of the surrounding walls.

Endoscopic cyst excision was planned under general anesthesia. An uncinectomy and middle meatal antrostomy was done. Polypoidal tissue and pus was removed, and the cyst wall was dissected. The cyst was found to be eroding the posterolateral wall of the maxilla with protrusion of the fat in the pterygopalatine fossa. Apart from a small part of the cyst wall adhering onto the right maxillary artery, the cyst was excised *in toto*. The right upper second and third molars were extracted and the fistula was sutured intraorally. The nasal cavity was packed with ribbon gauze soaked in 2% acriflavine. The patient was found to have regurgitation of fluids into the maxillary sinus after pack removal on postoperative day 2. He was diagnosed to have an oroantral fistula. An obturator was inserted for the region to heal and after 2 weeks resuturing was attempted. The fistula closed completely. Follow-up endoscopy was found to be normal after 1 month.

Histopathology of the cyst was consistent with that of an OKC (Fig. 3).

DISCUSSION

Odontogenic keratocysts have an incidence of 5.4 to 17% of all odontogenic cysts.¹ In 1953, it was Philipsen and Reichart² who first described OKC, although it was only in 1963 that Pindborg and Hansen³ described their main features. As OKC behaves like a benign tumor, it has been renamed by World Health Organization as keratocystic odontogenic tumor as suggested by Philipsen in view of its tendency for malignant transformation into squamous cell carcinoma (with an incidence of 0.12%).^{4,5} Odontogenic keratocysts are more common in the mandible, with cysts in the maxilla having incidence of 31.3% only. In the maxilla, they most commonly occur in the canine region.⁶

Odontogenic keratocysts arise from cell rests of dental lamina and can be defined as “a benign uni or multicystic

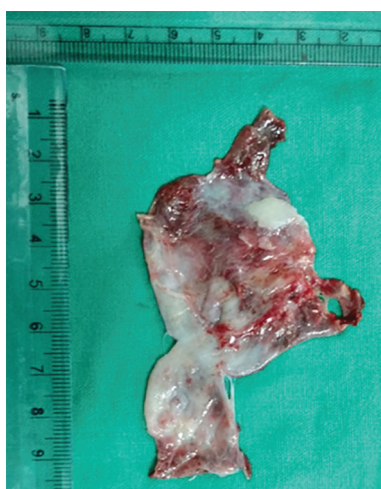

Fig. 2: Cyst wall after complete excision of the cyst

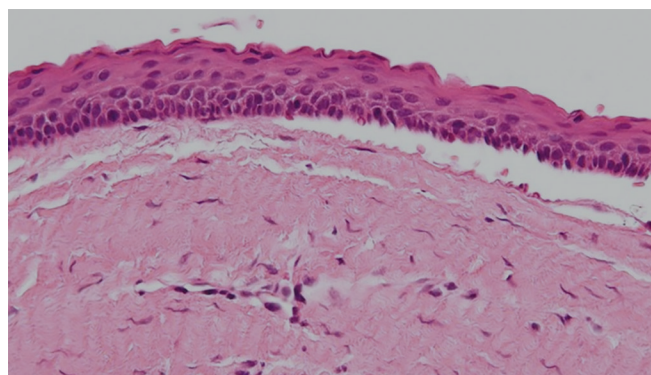


Fig. 3: Hematoxylin and eosin stain of the specimen showing features consistent with that of an OKC (magnification: 400×)

intraosseous tumor of odontogenic origin with a characteristic lining of pseudostratified squamous epithelium and potentially aggressive infiltrative behavior."⁷ Odontogenic keratocysts occur either in the second and third decade or in the fifth decade, hence, showing a bimodal age incidence.⁶

The rarity of this case presentation is in the fact that only 1% of maxillary OKCs will show involvement of maxillary sinus, which was seen in both our patients.⁸ Odontogenic keratocysts have been further subdivided as parakeratinized and orthokeratinized cysts by Cawson and Odell⁹ in 2004.

Histopathologically, OKCs have about 8 to 10 epithelial layers, with the basal layer sometimes showing invasion into surrounding connective tissue forming microsatellite cysts. Tendency of postsurgical recurrence is higher with the presence of these microsatellite cysts (as high as 10–60%).¹⁰

Radiologically, OKCs on CT imaging may show a uni- or multilocular cystic lesion with thin and smooth bony walls due to invasion of the adjacent "scaloped" bone. Magnetic resonance (MR) imaging of the cystic contents of OKC shows predominantly intermediate to low signal on T2, and intermediate to high signal on T1. Hence, MR may be superior to CT to differentiate it from other odontogenic cysts.¹¹

Historically, OKCs have been treated by open approaches like Caldwell Luc. However, with the advent of endoscopic sinus surgery, there is an increasing trend to treat maxillary sinus OKCs via the endoscopic route. When compared with the conventional procedures, endoscopic approach is less invasive and can prevent complications like chronic sinusitis and oroantral fistula. Better endoscopic visualization also implies complete removal of the cyst, hence, decreasing the chances of recurrence and morbidity. There is also

lesser chance of infection and need for postoperative drainage in case of endoscopic approach. Endoscopic endonasal approach was used in both of our cases for excision of the cysts.

REFERENCES

1. Daley TD, Wysocki GP, Pringle GA. Relative incidence of odontogenic tumors and oral and jaw cysts in a Canadian population. *Oral Surg Oral Med Oral Pathol* 1994 Mar;77(3):276-280.
2. Philipsen HP, Reichart PA. Classification of odontogenic tumours. A historical review. *J Oral Pathol Med* 2006 Oct;35(9):525-529.
3. Pindborg JJ, Hansen J. Studies on odontogenic cyst epithelium. 2. Clinical and roentgenologic aspects of odontogenic keratocysts. *Acta Pathol Microbiol Scand* 1963;58:283-294.
4. Chirapathomsakul D, Sastravaha P, Jansisyanont P. A review of odontogenic keratocysts and the behaviour of recurrences. *Oral Surg Oral Med Oral Pathol Oral Radiol Endod* 2006 Jan;101(1):5-9, discussion 10.
5. Timoșca GC, Cotuțiu C, Gavriliță L. Malignant transformation of odontogenic cysts. *Rev Stomatol Chir Maxillofac* 1995 Feb;96(2):88-95.
6. Shear, M.; Speight, PM. Cysts of the oral and maxillofacial regions. 4th ed. Oxford: Blackwell Munksgaard; 2007. p. 6-58.
7. Sansare K, Raghav M, Mupparapu M, Mundada N, Karjodkar FR, Bansal S, Desai R. Keratocystic odontogenic tumor: systematic review with analysis of 72 additional cases from Mumbai, India. *Oral Surg Oral Med Oral Pathol Oral Radiol* 2013 Jan;115(1):128-139.
8. Gomes CC, Diniz MG, Gomez RS. Review of the molecular pathogenesis of the odontogenic keratocyst. *Oral Oncol* 2009 Dec;45(12):1011-1014.
9. Cawson, RA.; Odell, EW. Essentials of oral pathology and oral medicine. 6th ed. New York: Churchill Livingstone; 1998. p. 97.
10. Ide F, Shimoyama T, Horie N. Peripheral odontogenic keratocyst: a report of 2 cases. *J Periodontol* 2002 Sep;73(9):1079-1081.
11. de Zinis, LOR.; Mortini, P.; Farina, D.; Mossi, F. Expansile lesions arising from structures and spaces adjacent to the paranasal sinuses. In: Maroldi R, Nicolai P, editors. *Imaging in treatment planning for sinonasal diseases*. Berlin/Heidelberg: Springer; 2005. pp. 221-254.