

A Rare Case of Tuberos Xanthoma of Nose: A Case Report

Somashekara KG¹, Apurva A Jarandikar², Lakshmi Shantharam³, Hemalatha Mahantappa⁴

Received on: 08 April 2020; Accepted on: 06 June 2023; Published on: 21 March 2024

ABSTRACT

Xanthomas are localized lipid deposits in organs that may manifest as papules, plaques, or nodules on skin. There are many variants of xanthomas, and tuberous xanthoma is one of the xanthomas. They are very rare in head and neck region and xanthoma of the nose has been reported only once before. Xanthomas elsewhere are excised mainly for diagnostic purpose, whereas our patient wanted excision for better cosmetic appearance of the nose. We are presenting this case for its rarity and for concerns in management with review of literature. Facial xanthoma management requires excision for diagnosis and cosmesis. However, management of underlying lipid disorder is also very essential.

Keywords: Benign fibrous histiocytoma, Case report, Deformed nose, Nasal septum, Nose, Open rhinoplasty, Paranasal sinus.

Clinical Rhinology (2023); 10.5005/jp-journals-10013-1389

INTRODUCTION

Papules, plaques, or nodules in the skin because of localized lipid deposition in the organs are called as xanthomas.¹ Xanthoma is a term derived from a Greek word "Xanthos" meaning yellow and describes the subcutaneous lipid deposits.² The clinical types of cutaneous xanthomas are eruptive, tuberous, tuberoeruptive, tendinous, plane (including xanthelasma), and verruciform.¹

Tuberous xanthomas are yellow-orange papules or nodules erupted over joints or extensor surfaces of the extremities, most commonly the elbows and knees. They may be solitary/multiple and can reach sizes up to 3 cm. They mainly occur in conditions like familial hypercholesterolemia (elevated low-density lipoprotein levels) or familial dysbetalipoproteinemia.¹

Frederickson has classified lipid metabolism disorders into five classes.³

Tendon and tuberous xanthomas are usually associated with familial hypercholesterolemia (type II hyperlipidemia) and broad beta-disease (type III hyperlipidemia).⁴

CASE DESCRIPTION

A 27-year-old female patient presented with swelling over the dorsum of nose for 2 years. It was small to begin with and had grown slowly over 2 years. It measured 4 × 3 cm when she presented. It was non-tender, firm on palpation, and without any other signs of inflammation. There was no nasal obstruction or nasal bleeding. She had similar swellings above the heel and on the left forearm. The swelling over the forearm was excised 6 months back for diagnostic purpose and it showed features of tuberous xanthoma. Now, the patient wanted the nasal mass to be removed for cosmetic purpose.

On further evaluation, she had mild mental retardation. Lipid profile was done. Total cholesterol was 217 mg/dL. HDL: 59 mg/dL, LDL: 103 mg/dL, VLDL: 55 mg/dL. Ultrasonography of abdomen and pelvis was normal. The 2D Echocardiography was also normal.

The mass over the dorsum of nose was excised by open structure rhinoplasty. A mid-columellar incision was applied. The dorsal skin was elevated to expose the nasal bones and cartilages. A yellowish colored mass was situated on the upper lateral cartilages extending over the nasal bones. The mass was separated from underlying structures and removed completely.

¹Department of ENT, KIMS, Bengaluru, Karnataka, India

²Department of ENT, PCMC PGI YCM Hospital, Pune, Maharashtra, India

³Department of ENT, Bhagavan Mahaveer Jain Hospital; Manasa Cochlear Implant Centre; Excelcare Hospital, Bengaluru, Karnataka, India

⁴Department of Pathology, KIMS, Bengaluru, Karnataka, India

Corresponding Author: Apurva A Jarandikar, Department of ENT, PCMC PGI YCM Hospital, Pune, Maharashtra, India, Phone: +91 9881446133, e-mail: apurvajarandikar@gmail.com

How to cite this article: Somashekara KG, Jarandikar AA, Shantharam L, *et al.* A Rare Case of Tuberous Xanthoma of Nose: A Case Report. *Clin Rhinol* 2023;14(1-3):20-22.

Source of support: Nil

Conflict of interest: None

Patient consent statement: The author(s) have obtained written informed consent from the patient for publication of the case report details and related images.

The gross specimen showed pale pink soft tissue measuring 4.5 × 2.0 × 1.2 cm. Cut section was yellowish. Microscopic examination of section showed sheets of foamy histiocytes (xanthoma cells) having vacuolated cytoplasm and pyknotic nuclei with interspersed inflammatory cells. These cells were surrounded by dense fibrocollagenous stroma. Few cholesterol clefts and multinucleated giant cells were seen. Diagnosis of tuberous xanthoma of the dorsum of nose was done.

The patient was followed up for 6 months. There was no recurrence and the patient was satisfied with cosmetic outcome. However, the patient is under follow-up with physicians for hypercholesterolemia (Figs 1 and 2).

DISCUSSION

Cutaneous xanthomas are often non-life-threatening and excision is done for cosmetic purpose. Possible association of hyperlipidemia requires evaluation and treatment. Xanthomas may be the cutaneous markers for underlying lipid metabolism disorders.³

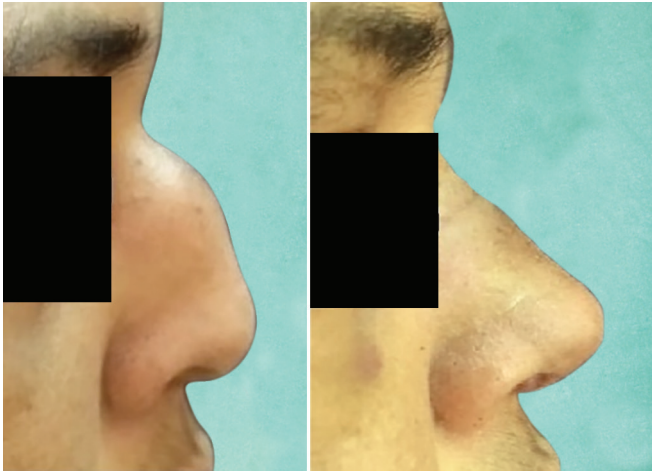


Fig. 1: Preoperative and postoperative appearance

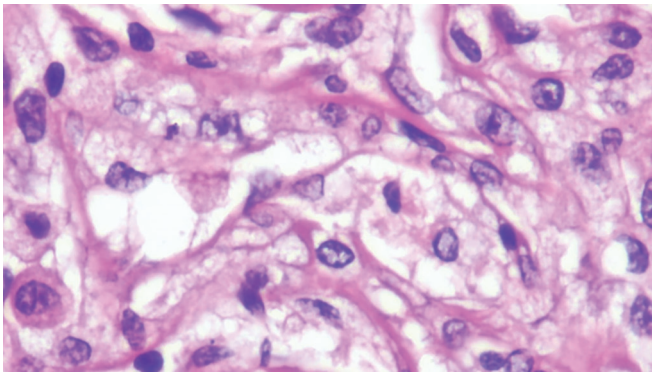


Fig. 2: H & E staining 40× magnification. Shows sheets of foamy histiocytes (xanthoma cells) having vacuolated cytoplasm and pyknotic nuclei separated by varying amount of fibrocollagenous stroma

Tuberous xanthomas are associated with type II hyperlipidemia which is characterized by familial hypercholesterolemia and type III hyperlipidemia characterized by broad beta-disease.⁴

Normolipidemic xanthomas are mostly seen as diffuse flat skin lesions, whereas hyperlipidemic types are polymorphous, tuberous affecting either skin, tendons, or joints.⁵ Xanthomas are diagnosed depending on their clinical presentation and sometimes skin biopsy report.

They are also seen over buttocks, hands, fingers, feet and patellar, and Achilles tendon.⁶

Solitary xanthomas have rarely been observed in the head and neck.⁶ Literature search showed few cases of solitary xanthomas of head and neck region (Table 1).⁷⁻¹⁰ Fujiwara S et al. have reported the first case of tuberous xanthoma of nose and cheeks in patient of type II familial hypercholesterolemia.¹¹

Tendinous and tuberous xanthomas are linked with autosomal dominant hypercholesterolemia, familial dyslipoproteinemia as well as for cerebrotendinous xanthomatosis and familial β -sitosterolemia.⁶

Tuberous xanthomas are well-circumscribed lesions in the connective tissue of skin, tendons, or fasciae predominantly consisting of foam cells. These specific cells are formed from macrophages due to excessive uptake of low-density lipoprotein

Table 1: Solitary xanthomas of head and neck region in literature⁶⁻¹⁰

Sr. No.	Authors	Year of publication	Region of solitary tuberous xanthoma
1.	Nam MH et al. ⁹	1987	Maxillary sinus
2.	Pitman M et al. ⁶	2002	Maxillary sinus
3.	Gustavo JA et al. ¹⁰	2003	Sphenoid sinus
4.	Muthuswamy KA et al. ⁷	2008	Bilateral temporal bone
5.	Morel D et al. ⁸	2016	Mandible

(LDL) particles and their oxidative modification.⁶ The process of xanthoma formation starts by an increased local extravasation of lipids through the vascular wall to the interstitial space of connective tissues. Phagocytosis of LDL aggregates and lipid complexes by monocytes and macrophages lead to formation of foam cells.⁶ These lipid-laden macrophages called as “foam cells” are the characteristic histologic feature of cutaneous xanthomas. The number of foam cells and the presence of inflammatory cells, extracellular lipid deposition and fibrosis vary with the type and age of the xanthoma.¹

Cutaneous xanthomas are not life-threatening and are usually asymptomatic. Therefore, treatment is not mandatory specifically for them, but it is often desired for cosmetic reasons.¹

Pharmacological treatment of dyslipidemia is usually indicated and often leads to concomitant improvement in xanthomas caused by hyperlipidemia.¹ Dietary modification and drug therapy with statins form the initial treatment strategy. Pharmacotherapy along with dietary modification generally suffices for patients with heterozygous form, but LDL-apheresis and liver transplantation may be required for those with the homozygous form.² But, tuberous and tendinous xanthomas are slower to regress during treatment of dyslipidemia. Traditionally, surgical excision is done with good cosmetic results. Other effective treatment methods include cryotherapy, 70% trichloroacetic acid chemical peels and treatment with carbon dioxide or erbium-doped yttrium aluminium garnet [Er:YAG] lasers.¹

We preferred open structure rhinoplasty to get a good visibility and complete excision. Recent advances include genetic diagnosis in the form of polymerase chain reaction and fibroblast cell culture techniques for LDL receptor and Apo B 100 gene defects. Liver-directed ex vivo gene therapy could be the treatment of choice in the future.²

SUMMARY

- Tuberous xanthoma of head and neck is very rare.
- Solitary tuberous xanthoma is possible on the nose and excision is done for cosmetic as well as diagnostic purpose.

CONCLUSION

Tuberous xanthomas of head and neck region are rare. Xanthomas are excised for diagnosis and cosmetic purpose. Hyperlipidemia needs to be addressed with prolonged follow-up. Though xanthomas of head and neck are rare, they should be in the differential diagnosis, when there is associated hyperlipidemia. This is a very rare case of tuberous xanthoma presenting on the nasal dorsum. A study with more number of subjects is needed to understand recurrence pattern and establish treatment protocol.

ORCID

Apurva A Jarandikar  <https://orcid.org/0000-0002-2885-7319>

Lakshmi Shantharam  <https://orcid.org/0000-0003-2293-6056>

REFERENCES

1. Vargas-Flores E, Lourdes Estrada-Alpizar E, Arenas-Osuna J. Tuberous xanthomatosis as a presentation of familial hypercholesterolemia. *JSM Clin Case Rep* 2016;4:1114. DOI: <https://doi.org/10.47739/2373-9819/1114>.
2. Pathania V, Yadav A. A case of familial hypercholesterolaemia Type IIa presenting with tuberous xanthomas. *Med J Armed Forces India* 2015;71(Suppl 1):S254–S256. DOI: 10.1016/j.mjafi.2014.07.004.
3. Babu R, Venkataram A, Santhosh S, et al. Giant Tuberous Xanthomas in a case of Type IIa Hypercholesterolemia. *J Cutan Aesthet Surg* 2012;5(3):204–206. DOI: 10.4103/0974-2077.101384.
4. Handa R, Gupta K, Wali JP. Normolipidemic xanthomatosis. *Postgrad Med J* 1995;71(839):555–556. DOI: 10.1136/pgmj.71.839.555.
5. Zak A, Zeman M, Slaby A, et al. Xanthomas: Clinical and Pathophysiological relations. *Biomed Pap Med Fac Univ Palacky Olomouc Czech Repub* 2014;158(2):181–188. DOI: 10.5507/bp.2014.016.
6. Pitman M, Elhosseiny A, Moscatello AL. Xanthoma of the maxillary sinus. *Otolaryngol Head Neck Surg* 2002;126(4):426–427. DOI: 10.1067/mhn.2002.123832.
7. Muthuswamy KA, Azmi K, Narayan P. Bilateral temporal bone xanthoma: Case report. *J Neurosurg* 2008;108(2):361–364. DOI: 10.3171/JNS/2008/108/2/0361.
8. Morel D, Kelsch RD, Nolan PJ. Primary xanthoma of the mandible: Report of a rare case. *Head Neck Pathol* 2016;10(2):245–251. DOI: 10.1007/s12105-015-0643-z.
9. Nam MH, Grande JP, Li CY, et al. Familial hypercholesterolemia with unusual foamy histiocytes. Report of a case with myelophthisic anemia and xanthoma of the maxillary sinus. *Am J Clin Pathol* 1988;89(4):556–561. DOI: 10.1093/ajcp/89.4.556.
10. Mercado G JA, Torre CA, Hernandez G, et al. Xanthoma of the Sphenoid Sinus: A Rare Presentation. *Otolaryngol Head and Neck Surg* 2013;149:266. DOI:10.1177/0194599813496044a374.
11. Fujiwara S, Oka M, Kunisada M, et al. Severe Xanthomatosis with prominent tuberous xanthomas on the cheeks and the nasal dorsum in a patient with type II hyperlipoproteinemia. *Eur J Dermatol* 2013;23(4):517–518. DOI: 10.1684/ejd.2013.2063.