

## CASE REPORT

# Concha Bullosa Osteoma: An Unusual Cause of Headache

<sup>1</sup>Pragya Singh, <sup>2</sup>Mahesh K Mittal, <sup>3</sup>Neeraj N Mathur, <sup>4</sup>Mukul Sinha

## ABSTRACT

**Aim and background:** Osteomas are common benign tumors of the paranasal sinuses, but are usually asymptomatic and found as a coincidental finding during routine radiological investigations. The aim is to demonstrate typical radiological findings of osteomas and demonstrate rare occurrence of osteoma in middle turbinate.

**Case report:** Patient presenting with recurrent headaches, left-sided facial pain, and intermittent nasal obstruction was evaluated using Philips Brilliance 40-multislice computed tomography scanner, which showed bilateral maxillary and ethmoid sinusitis with bilateral fluid-filled concha bullosa with left-sided concha bullosa showing a well-defined lesion of bone attenuation suggestive of osteoma.

**Conclusion:** Osteomas can rarely occur in nasal turbinates and may be symptomatic requiring endoscopic/surgical removal.

**Clinical significance:** Radiological investigations are diagnostic for osteomas and play an important role in preoperative planning. Osteomas arising from the turbinates are more easily accessible by endoscopy than sinus osteomas; hence, removal carries less risk. Therefore, it is important to diagnose nasal osteoma when it is small in size, follow it up, and resect it when its size is appropriate for endoscopic surgery.

**Keywords:** Concha bullosa, Endoscopic surgery, Neuralgia, Osteoma, Sinusitis.

**How to cite this article:** Singh P, Mittal MK, Mathur NN, Sinha M. Concha Bullosa Osteoma: An Unusual Cause of Headache. Clin Rhinol An Int J 2017;10(1):25-27.

**Source of support:** Nil

**Conflict of interest:** None

## INTRODUCTION

Nasal osteoma is a benign, slow-growing bone tumor that can be found more frequently in the maxillary, ethmoidal, and frontal sinuses. The occurrence of the osteoma in the middle turbinate is rare. We present a unique case of a

patient who underwent computed tomography (CT) of the brain and sinuses for investigation of headache, and osteoma in concha bullosa was found incidentally.

## CASE REPORT

A 35-year-old female presented to the ear–nose–throat outpatient clinic of the Safdarjung Hospital with recurrent headaches, left-sided facial pain, and intermittent nasal obstruction since last 1 year. She had no history of facial trauma or nasal surgery. Her past medical history was unremarkable. She had no family history of osteoma or colonic malignancies. A clinical diagnosis of sinusitis was made. Routine laboratory tests were normal.

Nasal endoscopy showed bilateral hypertrophied middle turbinates with normal mucosa.

## MATERIALS AND METHODS

Patient was evaluated using Philips Brilliance 40-multislice CT scanner (KV mAs, slice thickness). Volumetric CT of nose and paranasal sinuses (PNSs) was done with coronal and sagittal reformatting.

## RESULTS AND INTERPRETATION

The CT showed bilateral maxillary and ethmoid sinusitis with bilateral fluid-filled concha bullosa. Left-sided concha bullosa showed a well-defined lesion of bone attenuation measuring 2.8 × 2.6 cm (Figs 1A and B). There was no cribriform plate involvement. No extension to the skull base was observed. The radiological diagnosis of osteoma of left-sided aerated middle turbinate (concha bullosa) with chronic pansinusitis was made.

The patient was put on oral antibiotics, and endoscopic surgery for both pansinusitis and osteoma was considered. However, the patient did not give consent for surgery.

## DISCUSSION

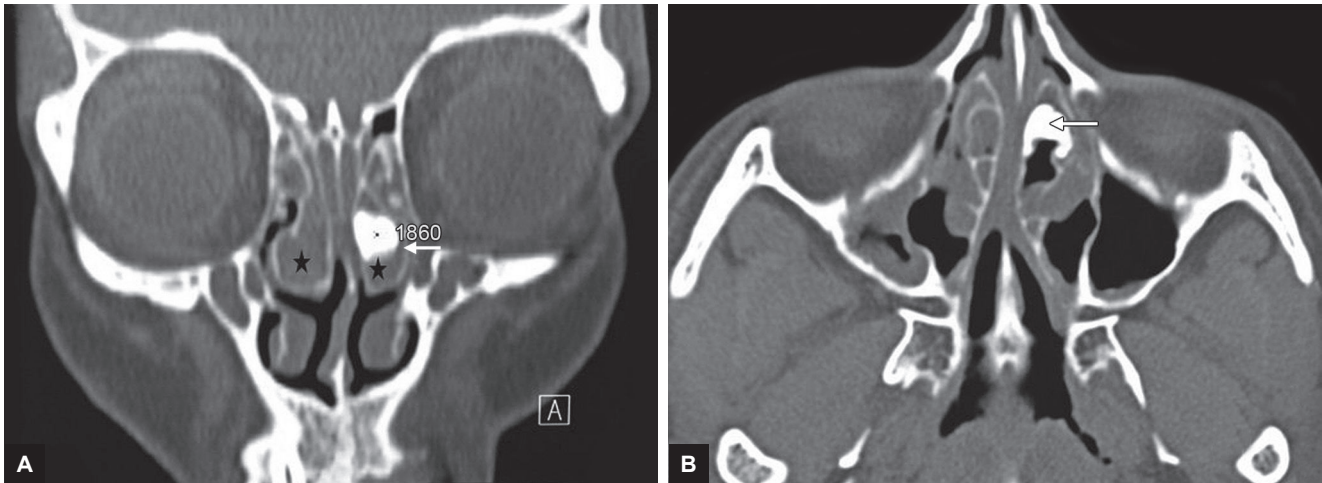
Osteoma is a benign, slow-growing bone tumor, which is commonly asymptomatic, being detected incidentally in 1% of plain sinus radiographs or in 3% of sinus CT scans.<sup>1</sup> It is a common tumor of PNSs, i.e., found more frequently in the maxillary, ethmoidal, and frontal sinuses. Presence of an osteoma in the nasal cavity is a rarely encountered situation.<sup>2</sup> Its incidence was reported to be as low as 0.6% in the literature.<sup>3</sup> Osteoma

<sup>1</sup>Senior Resident, <sup>2</sup>Professor and Consultant, <sup>3</sup>Director Professor and Head, <sup>4</sup>Senior Specialist

<sup>1,2,4</sup>Department of Radiodiagnosis, Vardhman Mahavir Medical College and Safdarjung Hospital, New Delhi, India

<sup>3</sup>Department of Otorhinolaryngology, Vardhman Mahavir Medical College and Safdarjung Hospital, New Delhi, India

**Corresponding Author:** Mahesh K Mittal, Professor and Consultant, Department of Radiodiagnosis, Vardhman Mahavir Medical College and Safdarjung Hospital, New Delhi, India Phone: +919810411459, e-mail: drmkmittal@rediffmail.com



**Figs 1A and B:** (A) Coronal and (B) axial CT images showing bilateral fluid-filled concha bullosa (star). Left aerated middle turbinate shows a well-defined lesion measuring  $2.8 \times 2.6$  cm of bone attenuation (solid arrow) suggestive of osteoma

in aerated middle turbinate is further extremely rare. Besides the turbinates, the nasal septum can also be the origin of nasal osteoma.

The etiology of osteomas arising from the PNSs can be embryological, traumatic, or infective. There are several theories regarding the origin of osteomas. The embryological theory postulates that osteomas arise at the junction of the embryonic cartilaginous ethmoid and membranous frontal bones.<sup>4</sup> However, many osteomas arise at sites distant from this junction. Sinusitis has been suspected in the etiology of osteoma formation, but the incidence of osteoma and infection do not correlate.<sup>5</sup> Trauma is another factor blamed in the formation of osteomas. However, many patients lack a history of trauma. The PNS osteomas are associated with higher prevalence of anatomical variations. This can be explained either by the stronger influence of genetic and environmental factors on the development of PNSs in patients with osteoma or by their higher susceptibility to above-mentioned factors.<sup>6</sup> Osteomas can also be a part of Gardner's syndrome, an autosomal dominant disease characterized by intestinal polyposis, osteomas, and cutaneous and soft tissue tumors.<sup>7</sup> In turbinate osteomas, no associated history of facial trauma or nasal surgery had been reported, and PNS infection appears to be the result of sinus meatal obstruction due to mass effect of the tumor.

Two different histopathologic types of osteomas have been described. Firstly, the ivory osteoma, composed of dense bone with only a minimal amount of fibrous tissue and secondly, the osteoma spongiosum, containing mature cancellous bone. Occasionally, a third variety called "mixed" osteoma contains features of both.<sup>8</sup>

The majority of osteomas are asymptomatic in the early stages and are diagnosed incidentally during radiological examination for the other conditions. In

symptomatic cases, the most common symptoms are progressive headache and chronic inflammation of the adjacent mucosa. Osteoma produces symptoms according to a "mass effect." When osteoma occurs in the paranasal cavity, an increase in the size of the mass may cause headache or chronic sinusitis. When they arise within the nose, the most common major complaint is nasal obstruction. The pressure exerted by the lesion may also give rise to symptoms, such as epiphora, diplopia, vision impairment, ophthalmalgia, and exophthalmos. Continued growth may completely obstruct the sinus ostia or nasal cavity and leads to the development of mucocele.<sup>9</sup> Middle turbinate osteoma has been reported to cause pneumocephalus after extending into the anterior cranial fossa.<sup>10</sup> Although symptoms are generally related to the size of the osteoma and its location, exceptions have been noted. Small osteomas have been reported as causing severe headache and needing surgical excision, while massive osteomas of the ethmoid sinus may remain asymptomatic.<sup>11</sup> Osteomas cause various problems and symptoms by producing pressure on neighboring structures. Left-sided facial pain and headache in our patient can be explained by any of the underlying mechanisms. The pressure created by the growth of the tumor can result in pain in the head as well as the face. Increased prostaglandin E2 synthesis suggests an important pathophysiological role as a mediator of the osteoma pain. The pain could be a kind of referred neuralgia (trigeminal neuralgia or nasociliary neuralgia). The sinuses and most of the anterior craniofacial structures are innervated by branches of the trigeminal sensory nerves. Any kind of noxious stimulation of the sinuses and adjacent structures will trigger afferent sensory volleys into the trigeminal ganglion. Also, pain is associated with nasociliary neuralgia due to impingement on the anterior ethmoidal nerve (Sluder's neuralgia).<sup>12</sup>

Osteomas can be detected by plain radiograph. The radiographic appearance is that of a dense well-circumscribed mass. Ivory osteomas are uniformly very dense, whereas mature osteomas may resemble "normal" bone with marrow space sometimes visible. However, it does not give detailed information of the lesion and it is not conducive for surgical interventions. The CT demonstrates a well-circumscribed mass of variable density, varying from very dense (similar in density to normal cortical bone) to less dense with a ground-glass appearance. They are seen either with a sinus or less commonly exophytically growing out of a sinus. The CT scan is an effective modality for the evaluation of osteomas, capable of detecting the extent of osteoma and invasion of the adjacent structures, namely the anterior cranial fossa, cribriform plate, and the orbit that may improve surgical decision making. Whillet and Quiney<sup>13</sup> treated an isolated middle turbinate osteoma by lateral rhinotomy and emphasized the presurgical role of CT to determine the extent of the lesion and its relations to vital structures.

In osteoma arising from the PNSs, surgical removal is indicated if it extends beyond the boundaries of the sinus, continues to enlarge, localizes in the region adjacent to the naso-frontal duct, or if signs of chronic sinusitis are present, regardless of size in symptomatic tumors. Surgical approaches are classified into external, endoscopic drill-out, and combined endoscopic and external procedures.<sup>14</sup> Although endoscopic removal is the preferred modality, the open approach should be considered to manage tumor involvement of the cribriform plate and frontal sinus.

Osteomas arising from the turbinates are more easily accessible by endoscopy than sinus osteomas; hence, removal carries less risk. Therefore, it is important to diagnose nasal osteoma when it is small in size, follow it up, and resect it when its size is appropriate for endoscopic surgery. Endoscopic surgery of nasal osteoma carries lower risk, except when the cribriform plate is involved, is technically easier, and leads to better cosmetic outcomes compared with endoscopic removal of sinus osteomas. Therefore, it appears clinically relevant to remove nasal osteoma. Since our patient refused surgery, the pathological diagnosis and confirmation of etiology of headache could not be done.

## CONCLUSION

Osteomas arising from the turbinates are rare, but an important cause of headaches and facial pain. Radiological

investigations are diagnostic for osteomas and play an important role in preoperative planning.

## CLINICAL SIGNIFICANCE

Osteomas arising from the turbinates are more easily accessible by endoscopy than sinus osteomas, hence removal carries less risk. Radiology plays an important role in diagnosis of nasal osteomas when it is small in size, following it up, and resecting it when its size is appropriate for endoscopic surgery.

## REFERENCES

1. Savic DL, Djerić DR. Indications for surgical treatment of osteomas of the frontal and ethmoid sinuses. *Clin Otolaryngol* 1990 Oct;15(5):397-404.
2. Viswanatha B. Middle turbinate osteoma. *Indian J Otolaryngol Head Neck Surg* 2008 Sep;60(3):266-268.
3. Mesolella M, Galli V, Testa D. Inferior turbinate osteoma: a rare cause of nasal obstruction. *Otolaryngol Head Neck Surg* 2005 Dec;133(6):989-991.
4. Seiden AM, El Hefny YI. Endoscopic trephination for the removal of frontal sinus osteoma. *Otolaryngol Head Neck Surg* 1995 Apr;112(4):607-611.
5. Menezes CO, Davidson TM. Endoscopic resection of a sphenoid osteoma. *Ear Nose Throat J* 1994 Aug;73(8):598-600.
6. Janovic A, Antic S, Rakocevic Z, Djuric M. Paranasal sinus osteoma: is there any association with anatomical variations? *Rhinology* 2013 Mar;51(1):54-60.
7. Bilkay U, Erdem O, Ozek C, Helvacı E, Kilic K, Ertan Y, Gurler T. Benign osteoma with Gardner syndrome: review of literature and report of a case. *J Craniofac Surg* 2004 May;15(3):506-509.
8. Ataman M, Ayas K, Gürsel B. Giant osteoma of the frontal sinus. *Rhinology* 1993 Dec;31(4):185-187.
9. Daneshi A, Jalessi M, Heshmatzade-Behzadi A. Middle turbinate osteoma. *Clin Exp Otorhinolaryngol* 2010 Dec;3(4):226-228.
10. Kutluhan A, Salviz M, Bozdemir K, De er HM, Culha I, Ozveren MF. Middle turbinate osteoma extending into anterior cranial fossa. *Auris Nasus Larynx* 2009 Dec;36(6):702-704.
11. Mansour AM, Salti H, Uwaydat S, Dakroub R, Bashshour Z. Ethmoid sinus osteoma presenting as epiphora and orbital cellulitis: case report and literature review. *Surv Ophthalmol* 1999 Mar-Apr;43(5):413-426.
12. Fenton RA. Osteoma causing nasociliary neuralgia. *Ann Otol Rhinol Laryngol* 1933;42:911-914.
13. Whillet HB, Quiney RE. Middle turbinate osteoma: an unusual cause of nasal obstruction. *J Laryngol Otol* 1988 Apr;102(4):359-361.
14. Streck P, Zagolski O, Skladzien J, Kurzynski M, Dyduch G. Osteomas of the paranasal sinuses: surgical treatment options. *Med Sci Monit* 2007 May;13(5):CR244-CR250.