

## CASE REPORT

# Bilateral Complete Congenital Choanal Atresia in an 18-month-old Female Child with Rare Clinical Presentation: Transnasal Endoscopic Repair with Stent

<sup>1</sup>Satyawati Mohindra, <sup>2</sup>Ashok K Gupta

## ABSTRACT

Congenital choanal atresia (CCA) is the developmental failure of the nasal cavity to communicate with the nasopharynx. Surgical repair is recommended in the first weeks of life in bilateral congenital choanal atresia (BCCA), because this is a life-threatening situation in newborns as they are obligate nose breathers. This article reports on an 18-month-old female child, with delayed presentation of bilateral choanal atresia, treated successfully endoscopically and stent placement postoperatively.

**Case report:** The patient is an 18-month-old female child, born full term, by cesarean section (for cephalopelvic disproportion) with birth weight 3,750 gm to a 30-year-old primigravida. There were no immediate prenatal or postnatal medical or surgical problems in the mother. The child cried immediately after birth, there was no postnatal respiratory distress, cyanosis, or any major hospital admission. On examination, microcephaly (head circumference 46 cm below 2 standard deviation of the mean), hypertelorism, anti-Mongolian slanted eyes, left side cleft lip with high arched palate with malocclusion were observed. She presented late with c/o nasal discharge and mild breathing difficulty on breastfeeding. The catheter test revealed the diagnosis of BCCA. Noncontrast computed tomography (CT) scan nose was done, which showed nonposterior choana blocked with bony plates on both the sides (Fig. 1). The paranasal sinuses, orbit, and anterior nasal cavities were within normal limits. Transnasal endoscopic repair was done under general anesthesia. Endoscopy revealed a bony atresia (Fig. 2), which was drilled out keeping the direction medially and inferiorly. Feeding tubes were fashioned as stents and placed for a period of 6 weeks. There were no postoperative complications. The patient was referred to pediatric surgery for other problems. Endoscopy confirmed bilateral patency at 12 weeks postoperatively.

**Keywords:** Congenital choanal atresia, Stent, Transnasal endoscopic repair.

**How to cite this article:** Mohindra S, Gupta AK. Bilateral Complete Congenital Choanal Atresia in an 18-month-old Female Child with Rare Clinical Presentation: Transnasal Endoscopic Repair with Stent. *Clin Rhinol An Int J* 2016;9(3):153-154.

<sup>1</sup>Additional Professor, <sup>2</sup>Professor and Head

<sup>1,2</sup>Department of Otolaryngology, Postgraduate Institute of Medical Education and Research, Chandigarh, India

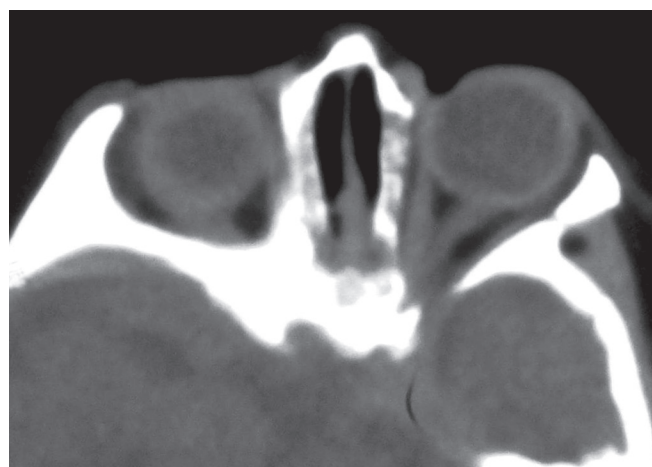**Corresponding Author:** Ashok K Gupta, Professor and Head, Department of Otolaryngology, Postgraduate Institute of Medical Education and Research, Chandigarh, India, Phone: +911722756763, e-mail: drashokpgi@hotmail.com

**Source of support:** Nil

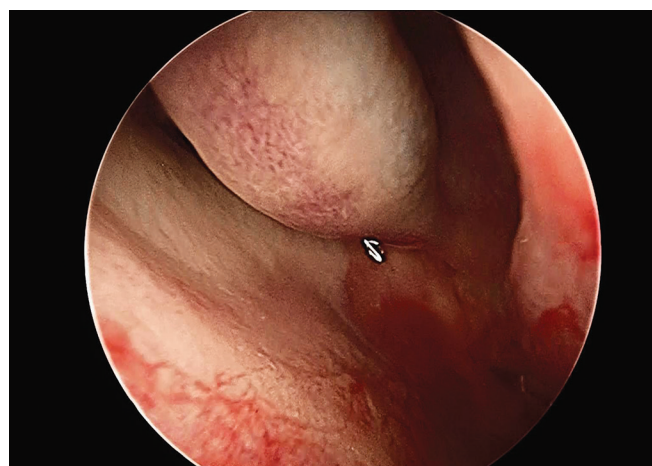
**Conflict of interest:** None

## INTRODUCTION

First described in 1755 by Roederer, congenital choanal atresia (CCA) is an infrequent anomaly, occurring in approximately 1 in 5,000–8,000 births.<sup>1</sup> Of these cases, 45% are bilateral. It is a condition that describes narrowing or obliteration of the posterior nasal aperture. It occurs more commonly in female patients.<sup>2</sup> It has been



**Fig. 1:** Noncontrast computed tomography scan nose was done which showed posterior choana blocked with bony plates on both the sides. the paranasal sinuses, orbit and anterior nasal cavities were within normal limits



**Fig. 2:** Endoscopic picture showing a bony atresia of left nasal cavity

thought that 90% of cases are bony and 10% are membranous. However, recent computed tomography (CT) and histopathological studies have shown that there are evidences of higher incidence of mixed bony and membranous anomalies (70%) and pure bony atresia (30%) with no pure membranous anomalies.<sup>3</sup>

There are some controversies about the etiology. Persisting bucconasal (membrane of Hochstetter) or buccopharyngeal membranes have been put forward as possible causes. Cinnamon,<sup>4</sup> however, suggested that the cause was due to proliferating epithelial cells within the nasal cavities during the 6th to 8th weeks of fetal development.

Patient with bilateral choanal atresia presents a respiratory emergency at birth, which requires urgent surgery. Even if respiratory tract obstruction is not severe, feeding difficulties with intermittent cyanosis are the classic presentation.<sup>5</sup> The ideal procedure for bilateral choanal atresia should restore the normal nasal passage, prevent damage to any growing structures, be safe, and have short surgery time and short hospitalization and convalescence with minimal morbidity and mortality.<sup>5,6</sup>

Here, we present a case of bilateral complete CCA with a rare delayed presentation. Our patient is an 18-month-old female child, who was born full term by cesarean section without any history of immediate or late postnatal respiratory distress, cyanosis, or any major hospital admission, presented late with c/o nasal discharge and mild breathing difficulty without any difficulty on breastfeeding. Endoscopic endonasal repair of the atretic part with stents was performed as an elective procedure under general anesthesia.

Many surgical approaches have been recorded over the last two centuries to correct the anomaly, including transnasal, transmaxillary, transseptal, and sublabial/transseptal. The benefit of placing intraoperative nasal

stents to improve patency rates has been evaluated in various studies. Transpalatal approach offers excellent exposure and high success rates. However, increased operative time, bleeding, palatal fistula, palatal muscle dysfunction, and maxillofacial disturbance, which occur in 50% of cases, are possible sequelae of this procedure.<sup>5</sup> Technical advances and experience in endoscopic nasal surgery and use of microdebriders and microdrills have provided the opportunity to use the transnasal endoscopic approach. This approach is less traumatic to surrounding structures and visualization is also excellent.

## CONCLUSION

Bilateral choanal atresia should always be considered wherever there are multiple facial anomalies in a child. Delay presentation is not unknown. Endoscopic approach offers an excellent way of treating these patients with minimal morbidity and interference with the surrounding structures.

## REFERENCES

1. Josephson GD, Vickery CL, Giles WC, Gross CW. Transnasal endoscopic repair of congenital choanal atresia. *Arch Otolaryngol Head Neck Surg* 1988 May;124(5):537-540.
2. Cumberworth VL, Diazeri B, Mackay IS. Endoscopic fenestration of choanal atresia. *J Laryngol Otol* 1995 Jan;109(1):31-35.
3. Brown OE, Pownell P, Manning SC. Choanal atresia: a new anatomic classification and clinical management applications. *Laryngoscope* 1996 Jan;106(1 Pt 1):97-101.
4. Pirsig W. Surgery of choanal atresia in infants and children: historical notes and undated review. *Int J Pediatr Otorhinolaryngol* 1986 Apr;11(2):153-170.
5. Khafagy YW. Endoscopic repair of bilateral congenital choanal atresia. *Laryngoscope* 2002 Feb;112(2):316-319.
6. Lazar RH, Younis RT. Transnasal repair of choanal atresia using telescopes. *Arch Otolaryngol Head Neck Surg* 1995 May;121(5):517-520.