

## CASE REPORT

# Sinonasal Mucormycosis with Fungal Ball: A Rare Case Report

<sup>1</sup>Rijuneeta Gupta, <sup>2</sup>Bhumika Gupta, <sup>3</sup>Amanjit Bal, <sup>4</sup>Ashok K Gupta

## ABSTRACT

Invasive mycotic infections can be effectively treated if rapid identification of fungus is obtained. We reported a case of coinfection by *Aspergillus* and *Rhizopus sp.* involving nose, paranasal sinuses and orbit in a 51 years old male patient diagnosed as diabetic on admission. He presented to ENT OPD with history of drooping of right upper eyelid, decreased vision right eye and deviation of angle of mouth to left side for 12 days. NCCT nose, PNS and orbit showed soft tissue density in right maxillary sinus, ethmoids and destruction of right inferior turbinate. MRI of nose, PNS and orbit revealed hypointense density in right maxillary and ethmoid sinuses on T1-weighted images and on T2-weighted; it was hyperintense. Patient underwent endoscopic debridement under general anesthesia and tissue was sent for microbiological and histopathological examination which confirmed presence of *Aspergillus* and *Rhizopus*. Patient responded to therapy with IV amphotericin B and surgical debridement. On discharge patient's condition was good.

**Keywords:** Mucormycosis, Fungal ball, Antifungals.

**How to cite this article:** Gupta R, Gupta B, Bal A, Gupta AK. Sinonasal Mucormycosis with Fungal Ball: A Rare Case Report. Clin Rhinol An Int J 2014;7(2):64-66.

**Source of support:** Nil

**Conflict of interest:** None declared

## INTRODUCTION

Fungal infection of paranasal sinuses is an increasingly recognized entity both in normal and immunocompromised individuals. A variety of different causative organisms are

responsible for paranasal mycosis, *Aspergillus* and *Zygomycetes* being the commonest.<sup>1</sup> The patients may have infection by one or more organisms. Reports of combined mucormycosis and aspergillosis infections limited to the oro-rhinocerebral region are very rare.<sup>2</sup> Coexistence of mucormycosis with fungal granuloma has not been reported. We present a case of patient with combined mucormycosis and fungal granuloma.

## CASE REPORT

A 51 years old male patient (Fig. 1) presented to our department with chief complaints of drooping of right upper eyelid, decreased vision right eye and deviation of angle of mouth to left side for 12 days. The complaints were sudden in onset and were rapidly progressive. These complaints were associated with blood stained discharge from right nostril, watering of right eye headache in right frontal region. There was no history of nasal obstruction, diplopia, fever, ear discharge or decreased hearing. Patient was not a known diabetic but after admission his sugars were found to be raised. On examination, there were blackish crusts in right nasal cavity and there was a whitish ulcer of 0.5 × 0.3 mm in right side of hard palate. On examination of right eye, there was a fixed frozen globe with mid dilated fixed pupil with no vision. Ptosis was also present. Hemoglobin was 7.6 gm%; serum electrolytes, renal and liver functions were within normal limits. Fundus examination showed peripapillary fluid reaching upto macula. NCCT nose, PNS and orbit

<sup>1,3</sup>Associate Professor, <sup>2</sup>Senior Resident, <sup>4</sup>Professor and Head

<sup>1,2</sup>Department of Otolaryngology and Head and Neck Surgery Postgraduate Institute of Medical Education and Research Chandigarh, India

<sup>3</sup>Department of Histopathology, Postgraduate Institute of Medical Education and Research, Chandigarh, India

<sup>4</sup>Department of Otolaryngology and Head and Neck Surgery (Unit II), Postgraduate Institute of Medical Education and Research, Chandigarh, India

**Corresponding Author:** Bhumika Gupta, Senior Resident Department of Otolaryngology and Head and Neck Surgery, Postgraduate Institute of Medical Education and Research, Chandigarh, India, Phone: 9418080419, e-mail: anubhumi802gmail.com

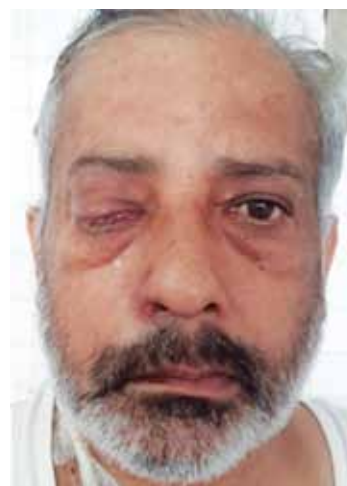

Fig. 1: Patient with right ptosis

(Fig. 2) showed STD in right maxillary sinus, ethmoids and destruction of right inferior turbinate. MRI of nose, PNS and orbit (Figs 3A and B) revealed hypointense density in right maxillary and ethmoid sinuses on T1-weighted images and on T2-weighted, it was hyperintense. Patient underwent nasal endoscopy and biopsy. Intraoperative findings were, necrosis of right inferior turbinate, middle turbinate and medial wall of maxilla. Mucosa of anterior and posterior ethmoids was hypertrophied and was taken out. Postoperative biopsy came out as mucormycosis with fungal granuloma (Figs 4A and B). Patient received 4 gm of liposomal amphotericin. Follow-up scans at 1.5 and 3 gm showed disappearance of disease but patient still had ptosis and facial palsy.

## DISCUSSION

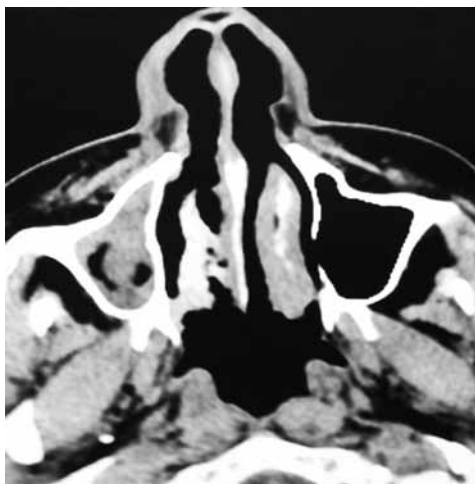
The fungi causing mucormycosis are opportunistic and can become fatal in debilitated patients if not treated in time. They have tendency to grow into vessels and lymphatics causing formation of mucus thrombi resulting in ischemia and infarction of the affected organ. The infection may spread rapidly

into the orbit and adjacent sinuses and may even extend intracranially either directly or via vessels. The fungus may cause cavernous sinus thrombosis leading to either unilateral or bilateral visual loss even within hours to days. Early diagnosis and treatment are must for better outcome. Treatment includes surgical debridement followed by antifungals and control of immunocompromised status of patient.

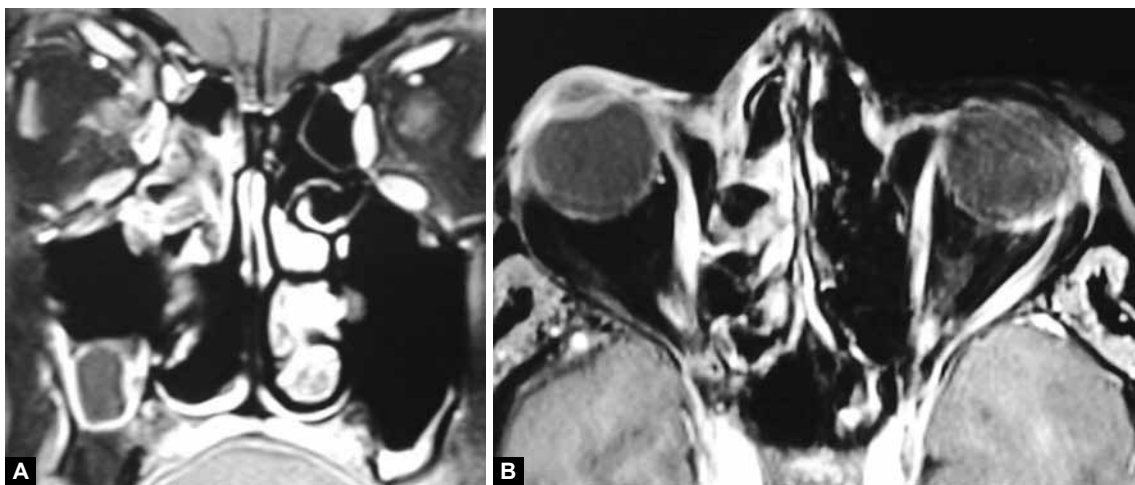On the other end, fungal ball is a completely noninvasive pathology seen in immunocompetent patients and has been described as accumulation of dense conglomeration of fungal hyphae in one sinus cavity, usually the maxillary sinus, although the disease may affect other sinuses or rarely multiple sinuses.<sup>3</sup> The disease is defined by radiologically opaque sinus with or without heterogeneity, mucopurulent cheesy or clay-like materials within sinus, a dense conglomeration of fungal hyphae separated from the sinus mucosa, nonspecific chronic inflammation of mucosa, no predominance of eosinophils or granuloma or allergic mucin, and no histopathological evidence of invasion.<sup>4</sup> Dhong et al showed that all fungal balls have a characteristic gritty matted gross appearance to the surgeon, whereas the majority, but not all, had radiological characteristic of heterogeneity.<sup>5</sup> The treatment of choice is surgical clearance. Antifungals are not required.

We report the case of a rare combined infection of mucormycosis and fungal granuloma in a patient with latent diabetes mellitus. The diagnosis was established on histopathological examination and specific culturing techniques. This combination of infection has not been reported in the literature yet to the best of our knowledge.

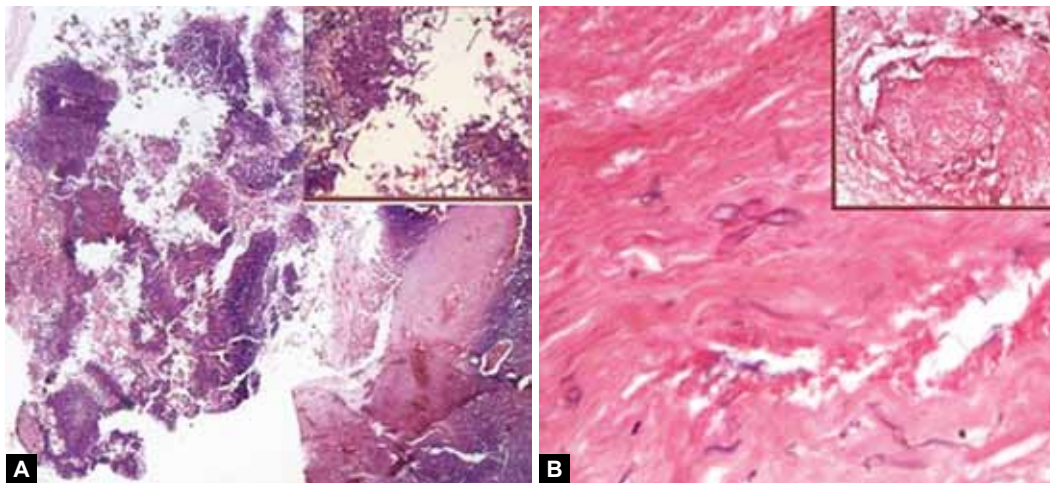
Alfano et al reported a case of 50 years old female who presented in diabetic ketoacidosis and was diagnosed having combined mucormycosis and aspergillosis of rhinocerebral region. Patient was managed with surgical debridement and antifungals. They concluded that early diagnosis, early anti-fungal treatment and early stabilization of the patients' general condition are fundamental for patient



**Fig. 2:** Computed tomography PNS showing right inferior turbinate destruction with soft tissue density in maxillary antrum



**Figs 3A and B:** T1-weighted MRI showing hypointense lesion in right ethmoids



**Figs 4A and B:** (A) Fungal granuloma with septate hyphae in high power (inset) and (B) mucormycosis with aseptate hyphae in high power (inset)

survival.<sup>6</sup> Vaidya D also reported a case of 68 years male with headache and proptosis and was diagnosed as having sinonasal mucormycosis and aspergillosis and was managed by surgical debridement and antifungals.<sup>7</sup> Maiorano E et al also reported a case of combined infection with mucormycosis and aspergillosis in a patient with Castleman's disease.<sup>8</sup>

Zygomycosis is a serious opportunistic infections that is commonly seen in immunocompromised patients. Since this fungus invade the vessels of the arterial system, a prompt diagnosis by direct examination of KOH mounts of clinical sample can confirm the diagnosis.<sup>9</sup> Preventive strategies like limiting the sources of contamination in the environment of patients at risk and careful monitoring of these patients can be effective in decreasing this infection. Finally, a better cooperation between clinicians, microbiologists, and pathologists is required in effective management of the disease to achieve a long-term and disease-free survival.

## REFERENCES

1. Alam BN, Chander GS, Sabhikhi, Bhatia M. 'Sinonasal mucormycosis: diagnosis using computed tomography.' *Medical Journal Armed Forces India* 2003;59(3):243-245.
2. Maiorano E, Favia G, Capodiferro S, et al. Combined mucormycosis and aspergillosis of the oro-sinonasal region in a patient affected by Castleman disease. *Virchows Arch* 2005;446(1): 28-33.
3. Grosjean P, Weber R. Fungus balls of the paranasal sinuses: a review. *Eur Arch Otolaryngol* 2007;264:461-470.
4. Deshazo RD, O'Brien M, Chapin K, et al. Criteria for the diagnosis of sinus mycetoma. *J Allergy Clin Immunol* 1997; 99:475-485.
5. Dhong HJ, Jung JY, Park JH. Diagnostic accuracy in sinus fungus balls: CT scan and operative findings. *Am J Rhinol* 2000; 14:227-231.
6. Alfano C, Chiummariello S, Dessy LA, Bistoni G, Scuderi N. Combined Mucormycosis and Aspergillosis of the Rhinocerebral Region. *In vivo* 2006;20:311-316.
7. Vaidya D, Shah P. Coinfection by *Aspergillus* and *Zygomycetes* Species in a Case of Acute Rhinosinusitis. *Case Reports in Otolaryngology* 2011; Article ID 382473, 5 pages.
8. Maiorano E, Favia G, Capodiferro S, Montagna MT, Lo Muzio L. Combined mucormycosis and aspergillosis of the oro-sinonasal region in a patient affected by Castleman disease. *Virchows Arch* 2005 Jan;446(1):28-33.
9. Malhotra S, Duggal S, Bhatia NK, Sharma N, Hans C. 'Rhinocerebral zygomycosis with pulmonary aspergillosis in a non-HIV-infected patient: an unusual case report from India.' *J Med Microbiol* 2009;58(1):146-150.