

## CASE REPORT

# Silent Sinus Syndrome in a Female Child with Enophthalmos and Diplopia

<sup>1</sup>Satyawati Mohindra, <sup>2</sup>Sandeep Mohindra, <sup>3</sup>Ashok K Gupta

## ABSTRACT

Opacification of the maxillary sinus was first published by Montgomery in the precomputerized era. The term silent sinus syndrome (SSS) was first used by Soparkar et al<sup>2</sup> in 1994. They defined an uncommon disease characterized by enophthalmos secondary to ipsilateral atelectasis of the maxillary sinus, even without nasal symptoms. The pathophysiology of SSS was demonstrated by Eto et al in 1993. In this report, we are presenting a case of silent sinus syndrome in a girl of pediatric age group, an unusual age of presentation.

**Keywords:** Enophthalmos, Silent sinus syndrome, Hypoglobus.

**How to cite this article:** Mohindra S, Mohindra S, Gupta AK. Silent Sinus Syndrome in a Female Child with Enophthalmos and Diplopia. Clin Rhinol An Int J 2014;7(1):40-42.

**Source of support:** Nil

**Conflict of interest:** None

## CASE REPORT

A 12-year-old girl presented to ENT outpatient department with a history of diplopia and unequal size of the eyes for the past 1 to 2 years. There were no ear nose or throat symptoms. Her past history was suggestive of recurrent attacks of upper respiratory tract infections and sinusitis during early childhood. Clinical examination revealed an enophthalmos of 5 mm on the right side, hypoglobus, restriction in elevation of the eye and diplopia in superior gaze (Fig. 1A).

Computed tomography (CT) scan (coronal view) revealed a smaller right maxillary sinus, with retraction of all the walls (Fig. 1B). A depression in the floor of orbit on the right side. Osteomeatal complex blockade was evident. Axial sections (Fig. 1C) revealed a hypoplastic maxillary sinus on right side and retraction of right orbit as compared to left side. An increase in the volume of right globe can be seen.

<sup>1,2</sup>Associate Professor, <sup>3</sup>Professor

<sup>1,3</sup>Department of Otolaryngology, Head and Neck Surgery Postgraduate Institute of Medical Education and Research Chandigarh, India

<sup>2</sup>Department of Neurosurgery, Postgraduate Institute of Medical Education and Research, Chandigarh, India

**Corresponding Author:** Satyawati Mohindra, Associate Professor, Department of Otolaryngology, Head and Neck Surgery, Postgraduate Institute of Medical Education and Research, Chandigarh, India, Phone: 09914209765, e-mail: satyamohindra@gmail.com, sandeepneuro@gmail.com

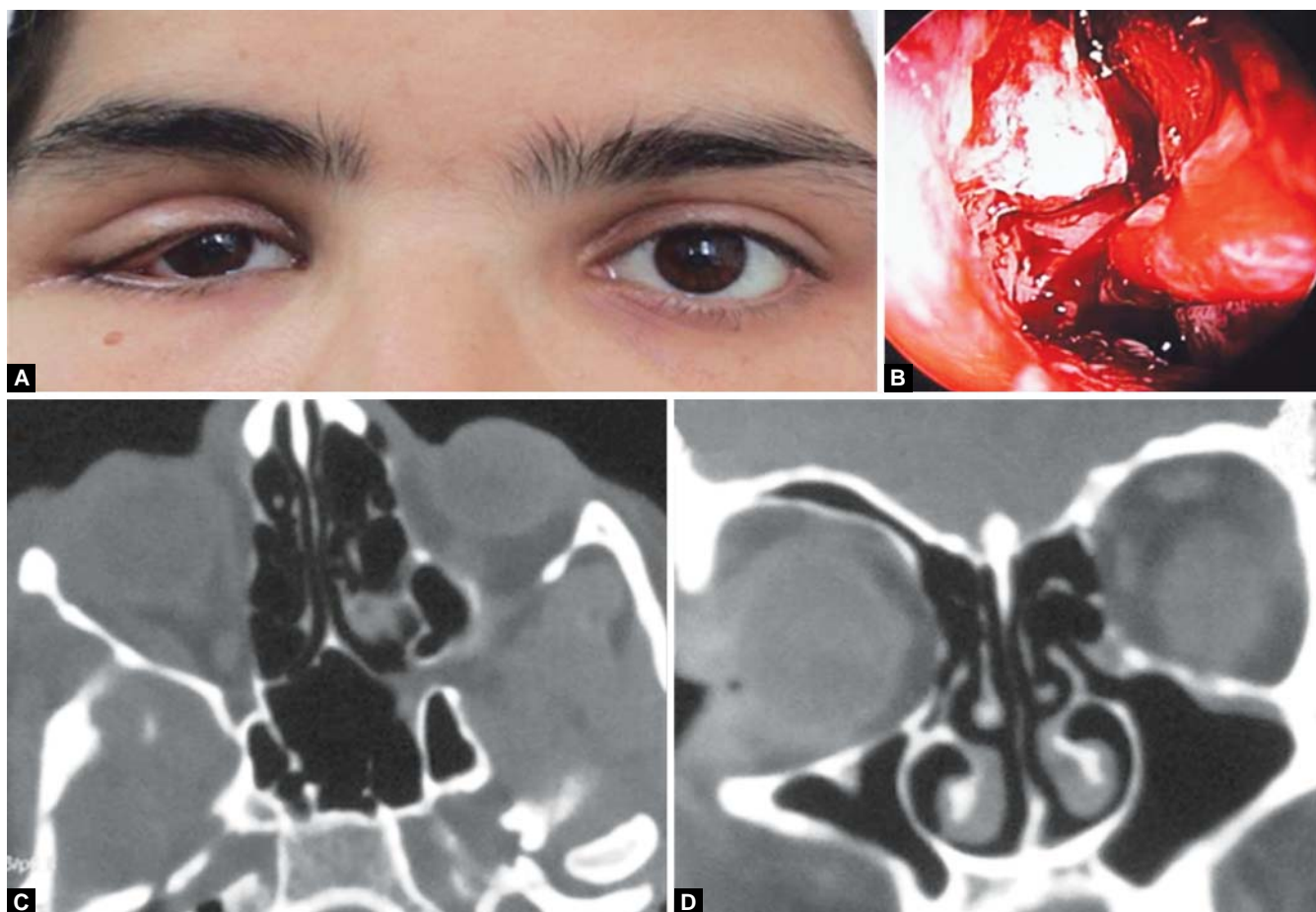
With a diagnosis of silent sinus syndrome on right side, the patient was taken up for functional endoscopic sinus surgery to maxillary sinus outflow tract blockade and reconstruction of orbital floor. There was mild DNS, the maxillary sinus was slightly lateralized. The osteomeatal complex was blocked with hypertrophied mucosa. The medial wall of the orbit along with the inferomedial angle was unusually prominent. Orbital floor was reconstructed with the help of septal cartilage via a subciliary approach (Fig. 1D). The patient's diplopia was improved immediately but the lower lid retraction remained for around 6 months. Now after a follow-up of 8 months, her eye symptoms have significantly improved.

## DISCUSSION

Opacification of the maxillary sinus was first published by Montgomery in the precomputerized era.<sup>1</sup> The term SSS was first used by Soparkar et al<sup>2</sup> in 1994. The pathophysiology of silent sinus syndrome (SSS) was demonstrated by Eto et al<sup>3</sup> in 1993. They concluded that enophthalmos stems from remodelling of the bony architecture of the sinus, secondary to its chronic obstructive disease. Complete obstruction induces continued negative pressure within the sinus, which activates the osteoclasts; in turn, these make the sinus walls thinner, leading to their collapse and the decent of the orbital floor with retraction of its walls. This then produces hypoglobus and enophthalmos.

Its prevalence is unknown. Approximately, 100 cases have been described in the literature. It typically affects individuals between the third and fifth decade of life, lacking dominance of gender or side.<sup>4</sup> We are reporting this in a patient in pediatric age group, with more severe orbital presentation which has not been done earlier.

Though the diagnosis is suspected on clinical examination, it is confirmed on radiology. Computed tomography usually shows inward retraction of sinus walls along with volume loss. This results in enlargement of middle meatus and an increased in orbital volume. There is always retracted and usually thinned orbital floor. Illneret et al reported five patients with SSS, among them, three patients showed inward retraction of all four sinus walls. All of them showed increased orbital volume on the same side.<sup>5</sup> It is crucial to diagnose SSS correctly because different conditions causing



**Figs 1A to D:** (A) Clinical picture depicting enophthalmos, lid retraction and narrowed palpebral fissure on the right side, (B) endoscopic view with a wide middle meatus. The unduly prominent inferomedial angle of the right orbit can be appreciated, (C) CT-axial sections showing enophthalmos on the right side and enlargement of the orbit as compared to the left and (D) CT-coronal sections showing a small right maxillary antrum with blocked osteomeatal complex, in drawing of all the walls and depression of orbital floor

spontaneous enophthalmos requires different treatment and carry a different prognosis. Tumor, trauma, congenital facial asymmetry, diffuse facial lipodystrophy, Parry-Romberg syndrome and linear scleroderma are common sources of incorrect diagnosis of SSS.<sup>6</sup>

The treatment is done to restore a normal ventilation of the maxillary sinus and the normal position of the ocular globe.<sup>7</sup> A procedure called the Caldwell-Luc was common in the past. Today, the gold standard treatment to restore sinus function and preserving the maxillary structures is functional endoscopic surgery with uncinectomy and antrostomy.<sup>8</sup> The orbital floor reconstruction is controversial. There are reports of considering it as a second-stage operation, which is commonly done 2 months after the sinus surgery, due to complete or partial resolution of the enophthalmos, with over-correction in the case of immediate orbital floor reconstruction resulting from the resolution of the hypo-ventilation and restoration of the normal intrasinus pressure. It is also noticeable that in cases with severe enophthalmos, reconstruction of the orbital floor is inevitable and morbidity, patient discomfort and hospitalization can be reduced by a single-stage operation. Due to negative sinus cultures in most

cases, by performing primary reconstruction, there would be no risk of infection.<sup>9</sup> We performed orbital reconstruction primarily to relieve diplopia which is quite incapacitating. Due to displacement of orbital wall and presentation of the inferomedial angle in the meatus it was safely done via subciliary approach. The patient is significantly improved at 8 months of follow-up.

## CONCLUSION

Though silent sinus syndrome presents in later age group, it may begin in pediatric age group as evident from our case. Since, the complications of SSS, such as upper lid retraction, malar depression, facial asymmetry, diplopia and enophthalmos, can be prevented by early diagnosis, a high index of suspicion must be exercised.

## REFERENCES

1. Montgomery WW. Mucocele of the maxillary sinus causing enophthalmos. *Eye Ear Nose Throat Mon* 1964 May;43:41-44.
2. Soparkar CN, Patrinely JR, Cuaycong MJ, Dailey RA, Kersten RC, Rubin PA, Linberg JV, Howard GR, Donovan DT, Matoba AY, et al. The silent sinus syndrome: a cause of spontaneous enophthalmos. *Ophthalmology* 1994 Apr;101(4):772-778.

3. Eto RT1, House JM. Enophthalmos, a sequela of maxillary sinusitis. *Am J Neuroradiol* 1995 Apr;16(Suppl 4):939-941.
4. Cardesín A, Escamilla Y, Romera M, Molina JA. Single surgical step for endoscopic surgery and orbital reconstruction of a silent sinus syndrome. *Acta Otorhinolaryngol Esp* 2013 Jul-Aug;64(4):297-299.
5. Sheikhi M1, Jalalian F. The silent sinus syndrome. *Dent Res J (Isfahan)* 2013 Mar;10(2):264-267.
6. Monos T, Levy J, Lifshitz T, Puterman M. The silent sinus syndrome. *Isr Med Assoc J* 2005 May;7(5):333-335.
7. Sánchez-Dalmau BF, Pascual L, Lao X, Maiz J. Sinus syndrome, an uncommon cause of enophthalmos. *Arch Soc Esp Oftalmol* 2008;83:125-128.
8. Sesenna E, Oretti G, Anghinoni ML, Ferri A. Simultaneous management of the enophthalmos and sinus pathology in silent sinus syndrome: A report of three cases. *J Craniomaxillofac Surg* 2010;38:469-472.
9. Behbehani R, Vacareza N, Bilyk JR, Rubin PA, Pribitkin EA. Simultaneous endoscopic antrostomy and orbital reconstruction in silent sinus syndrome. *Orbit* 2006;25:97-101.