

Sinonasal Teratocarcinoma: A Rare Clinical Entity managed by Medial Maxillectomy and Adjuvant Chemoradiation

Sudhir M Naik, Nanjundappa, Rajshekar Halkud, Srihariprasad, K Sidappa, Sumit Gupta, Clementina Rama Rao

ABSTRACT

Background/objectives: Sinonasal teratocarcinoma is a rare aggressive malignant tumor arising in the sinonasal tract and a malignant neoplasm of uncertain histogenesis. As the tumor contains various components of teratoma, sarcoma and carcinoma arising from cells of embryonic origin majority of the patients suffer locoregional failure.

Case report: A 35-year-old patient reported with history of left-sided nasal obstruction since 2 months. A polypoid mass was seen in the left nasal cavity and a clinical diagnosis of infected antrochoanal polyp endoscopic sinus surgery was done. Histopathology with immunohistochemistry confirmation yielded the report as teratocarcinoma.

Intervention: Medial maxillectomy with a Moure's incision was done with adjuvant intensity modulated radiotherapy and chemotherapy. Histopathological analysis of the specimen confirmed the earlier pathology.

Conclusion: Sinonasal teratocarcinoma has a proven poor prognosis with locoregional recurrence. The disease free survival rate is nearly 28% and overall survival rate is of 46%. Optimal resection margins are to be defined and multimodality treatment in the form of postoperative radiotherapy and chemotherapy are to be standardized.

Keywords: Teratocarcinoma, Sinonasal, Immunohistochemistry, Medial maxillectomy, Multimodality treatment.

How to cite this article: Naik SM, Nanjundappa, Halkud R, Srihariprasad, Sidappa K, Gupta S, Rao CR. Sinonasal Teratocarcinoma: A Rare Clinical Entity managed by Medial Maxillectomy and Adjuvant Chemoradiation. Clin Rhinol An Int J 2012;5(3):118-122.

Source of support: Nil

Conflict of interest: None declared

INTRODUCTION

Sinonasal teratocarcinoma is a rare aggressive malignant tumor arising in the sinonasal tract and a malignant neoplasm of uncertain histogenesis.¹⁻³ As the tumor contains various components of teratoma, sarcoma and carcinoma arising from cells of embryonic origin majority of the patients suffer locoregional failure.^{4,5}

Heffner and Hyams coined the term 'teratocarcinoma' based on a clinicopathological study of 20 patients with sinonasal tract neoplasms.⁴ The majority of reports have focused on pathology and immunohistochemistry and earlier these tumors were reported as teratoid carcinosarcoma, blastoma and malignant teratoma.⁵⁻⁸ The rare presentation of the tumor and varied combination of histopathological

features, with its infrequency and the complex phenotypic composition the lesions are often misdiagnosed, leading to management difficulties.^{3,9-12}

These tumors arising in the sinonasal tract has an insidious course and becomes symptomatic only after invading surrounding tissues in advanced stages making the overall prognosis poor.³ As the literature review about the tumor is limited and management protocols are not defined a multimodality treatment including surgery, radiation and chemotherapy appears an optimal approach.³

Here, we report a case of sinonasal teratocarcinoma managed by medial maxillectomy with postoperative intensity modulated radiotherapy and adjuvant chemotherapy.

CASE REPORT

A 35-year-old patient reported with history of left-sided nasal obstruction since 2 months. On examination a polypoid mass was seen in the left nasal cavity and clinical diagnosis of infected antrochoanal polyp was done.

With the clinical diagnosis of sinonasal polyp with chronic bilateral maxillary sinusitis computed tomographic (CT) scan was advised. The scan revealed soft tissue attenuation noted in the left sphenoidal and ethmoidal sinuses, which is seen extending to the left nasal cavity and posteriorly up to the nasopharynx measuring $6.6 \times 4.2 \times 2$ cm. The lesion is moderately enhancing on postcontrast study. Medically, the lesion is limited by the nasal septum and laterally by the lamina papyracea, medial maxillary wall and by the nasal bone. Superiorly, it is limited by the cribriform plate of the ethmoidal bone. Nodular mucosal thickening was noted in both maxillary sinuses. The osteomeatal complex on the left side is obliterated by the sinonasal mass. Frontal sinus and frontoethmoidal recesses are normal. Right osteomeatal complex is normal. The uncinate process is normal. The infundibular air lucency is normal. Right maxillary ostea is normal. Crista galli, cribriform plates and fovea ethmoidalis are normal (Figs 1 to 3).

Endoscopic sinus surgery for the nasal polyp was done and the excised polyp sent for histology showed a picture suggestive of small round cell tumor possibly olfactory neuroblastoma. The sections had pseudostratified columnar epithelium with squamous metaplasia and an underlying

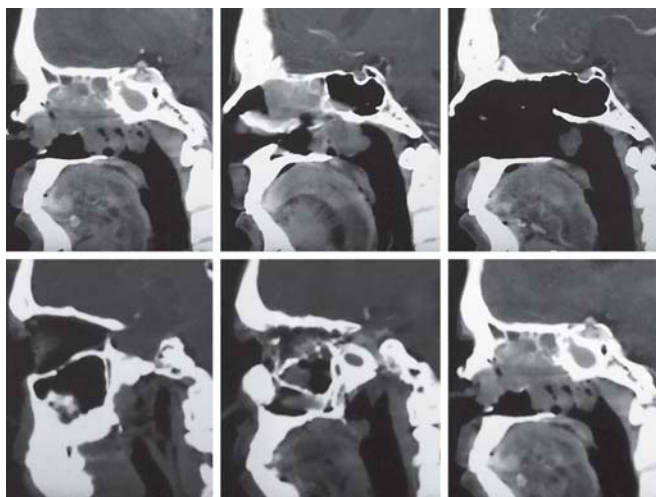


Fig. 1: Sagittal cuts on CT scan showing the posterior extent of the tumor

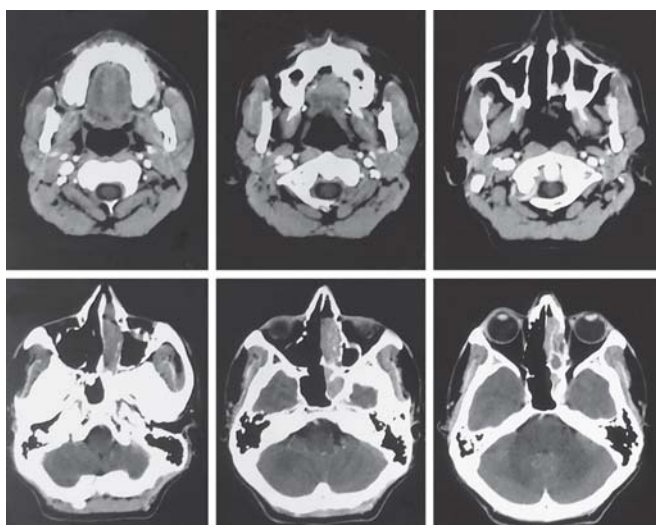


Fig. 2: Axial cuts showing the left sinomaxillary tumor

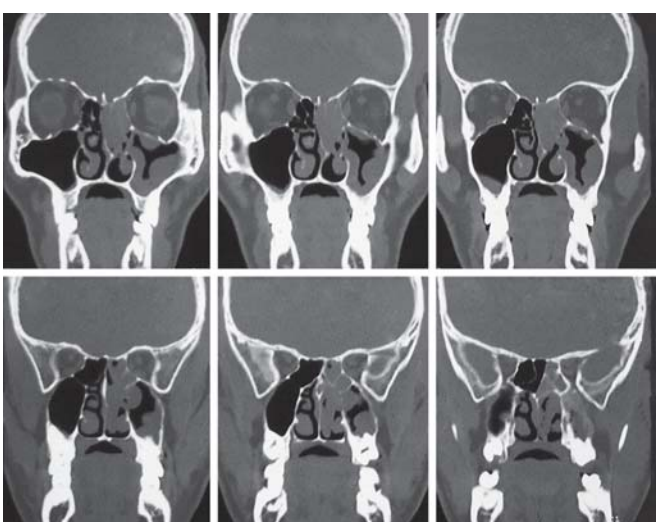


Fig. 3: Coronal cuts showing the ethmoidal and the inflammatory component of the tumor

neoplasm consisting of nests. The case was referred to us for further management and a slide review suggested of

teratocarcinosarcoma. Further, tumor showed desmin, MyoD1, chromogranin and synaptophysin positivity in the round cell and spindle cell areas. The epithelial areas were positive for cytokeratin and epithelial membrane antigen. S100 and Mic 2 were negative. Thus, a histopathologic and immunohistochemical diagnosis of teratocarcinosarcoma was made. A repeat CT scan of the paranasal sinuses was done and the large dense tumor in the left nasal cavity extending into the nasopharynx was seen and the ostia of all the sinuses were blocked leading to haziness.

We evaluated the case and planned for medial maxillectomy and wide excision of the tumor with exploration of the sinuses and septum. Medial maxillectomy was done by a lateral rhinotomy with extended Moure's incision. The nasal cavity was defined with the mass arising from the mucosa of the turbinates lateral wall involving the nasal septum. The irregular ulceroproliferative mass filling the cavity were removed by medial maxillectomy with exploration of the ethmoidal sinus, sphenoids and nasopharynx. The cavity was closed by BIPP packs and hemostasis maintained. The packs were removed after 7 days and the sutures on the 10th day (Fig. 4). The disease was confirmed on histopathology. The patient was given intensity modulated radiotherapy with 66 Gy in 33 fractions and adjuvant chemotherapy (Fig. 5).

DISCUSSION

Sinonasal teratocarcinosarcoma microscopically consists of primitive neuroepithelial elements with various malignant epithelial and mesenchymal components probably originating from stem or pluripotent progenitor cell with multidirectional differentiation.^{13,14}

Usually, squamous cell or adenocarcinoma is seen and the mesenchymal component shows spindle, smooth, skeletal muscle, cartilage and bone features.⁶ Common

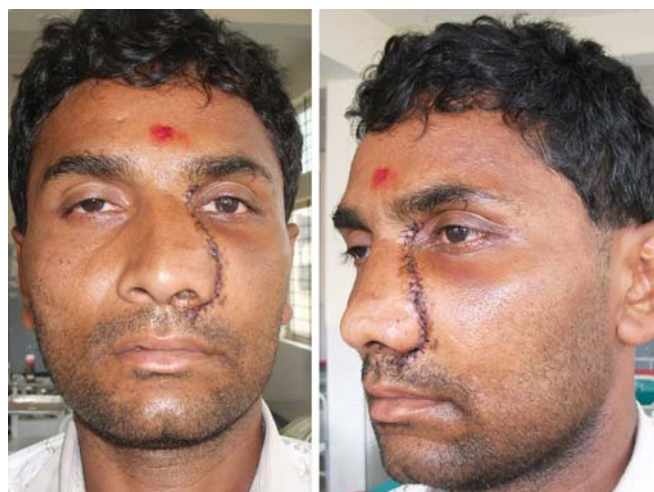

Fig. 4: The patient on the 10th postoperative day

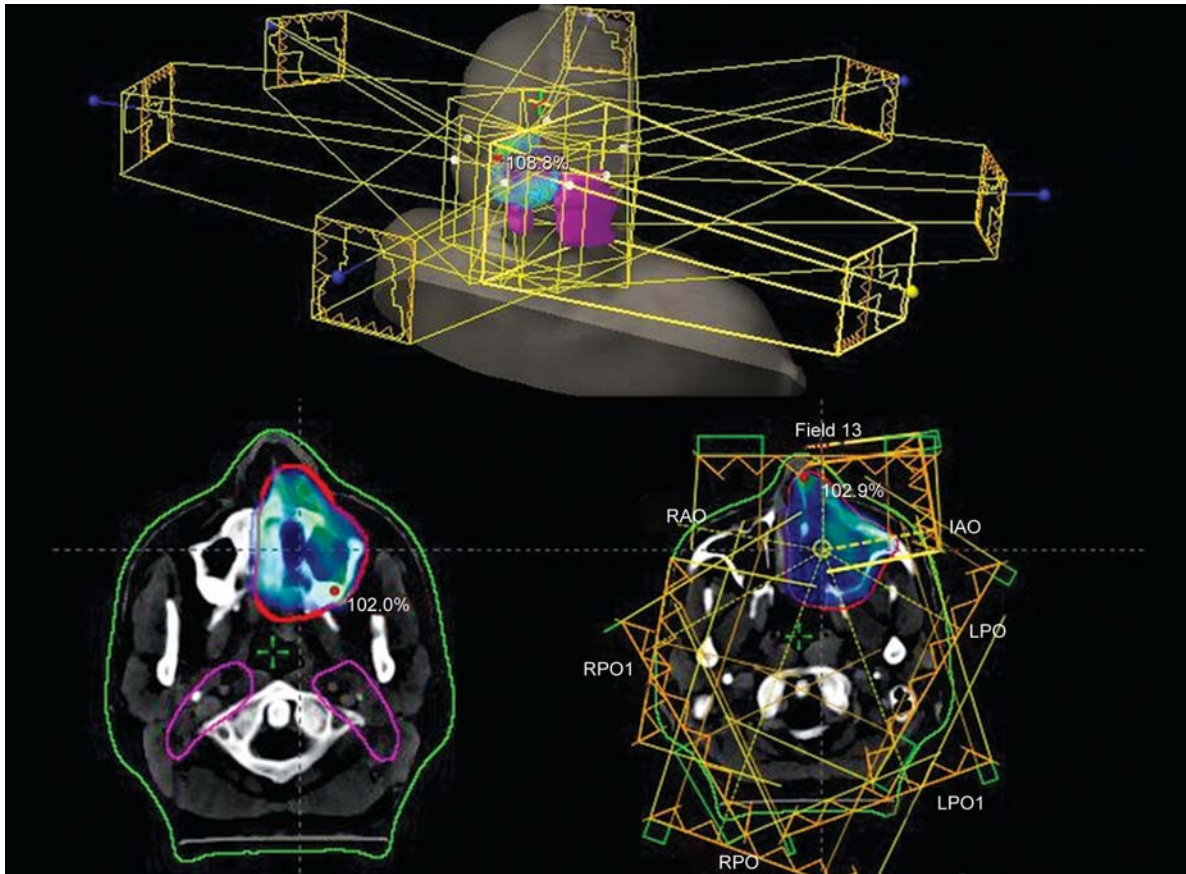


Fig. 5: Intensity modulated radiotherapy planned aiming specifically the tumor

clinical features include nasal obstruction and epistaxis with the average duration of symptoms being reported at 3.5 months.⁶ Incidence is seven times higher in males.^{15,16} No major meta-analysis is done on the tumor studies as most literature are case reports and series where the authors widely vary clinical features, management techniques and biological outcomes.^{9,17}

Clinical behavior and treatment modalities are not stressed in these studies and more of a histopathology, differential diagnosis and tissues of origin were remarked.^{18,19} Three landmark case series studies done in the past 3 decades have tried to emphasize on clinical features and treatment options of these tumors.⁸ Currently, 97 cases have been reported in world literature.³ Heffner and Hyams proposed and justified the term 'teratocarcinosarcoma' in his series on 20 patients.⁴ They ranged from 18 to 79 years with median age of 60 years.⁴ The histological features differed from gonadal germ cell neoplasms.⁴ They suggested aggressive multimodality method of treatment as only 40% of the patients lived more than 3 years and the average follow-up was 6.1 years.⁴

Smith et al reported a study of 10 cases where all were males ranging from 39 to 65 years.⁶ All presented with brief history of epistaxis and nasal obstruction.⁶ Also features of facial pain, expectoration of tissue, epiphora, headache,

vision loss, exophthalmos and anosmia were reported with an average duration of symptoms of 3.5 months.⁶

Microscopically, variable phenotypic features representing the main histogenetic components of the tumor are usually seen like the malignant neuroepithelial elements and various epithelial and mesenchymal malignant components.⁶ Adenocarcinoma and squamous carcinoma were seen in eight cases, rhabdomyosarcoma in six and chondrosarcoma areas were seen in two cases.⁶ CT review revealed tumor in nine cases localized to the nasal cavity, six were left sided, four were right sided, five were extension to the maxillary sinus, six were extension to the ethmoids and two to the sphenoids.⁶

All the tumors presented with extension to adjacent structures and the site origin could not be determined due to the rapid growth.⁶ They advocated complete surgical removal and postoperative adjuvant therapy due marked phenotypic heterogeneity of these tumors.²⁰ Among the 10 cases, nine underwent surgery and postoperative radiotherapy, one who received chemotherapy and radiotherapy, developed cervical metastasis and died of disease.⁶ On follow-up, five had no evidence of recurrence, one lost due to follow-up and three died due to locoregional failure.⁶

Budrukkar et al in their study on 22 cases found 21 males and a single female with more in younger adults.³

The median age was 44 years with the youngest being 10-year-old boy with sphenoid sinus bone erosion and neck nodes positive.³ All presented in advanced stages with five intracranial extension but neck nodes were seen only in one case.³ They reported varied amount of epithelial and connective tissue elements on microscopy. Immature cartilage, chondroid cells, smooth muscle cells, bone, neuronal tissue, squamous epithelium resembling fetal oral mucosa were reported.³ They proposed surgery as the first-line with adjuvant radiotherapy and chemotherapy as the multimodality management of choice.³ Surgery aimed at complete resection and adequate margins with radiation in form of 3D conformal radiotherapy or intensity modulated radiotherapy with adjuvant chemotherapy is advocated.³

Of the 22 cases diagnosed 16 completed treatment and were included in the study.³ Fourteen underwent surgery and two chemoradiation. Seven received adjuvant radiation therapy and four received adjuvant chemoradiation.³ Thirteen cases received radical radiation therapy, two chemoradiation alone and rest surgery and adjuvant radiotherapy with radiation doses ranging from 46 to 60 Gy in conventional fractionation. One patient had neck nodes at ipsilateral levels I and II nodes and no elective neck dissection was done.³ Budrukkar et al advised individualization of chemotherapy for every patient as the tumor consisted of different components and targeting the tumor with a particular regimen is impossible.³ A poor overall outcome were reported with persistent disease and locoregional recurrence being the cause.³ The disease free survival was 47% after 1 year, only 28% after 2 years and the median time of recurrence was 7 months. Median follow-up of survivors were 34 months with recurrence seen in 11 cases.³ Three cases had persistent primary disease, three had recurrence at primary disease and nodes, one at primary, two at nodes and two had distant metastasis.³

Shorter et al reported the first known case of this tumor with intracerebral metastasis managed via a multidisciplinary approach. They reported rare metastasis into the spinal axis, cervical lymph nodes and respiratory tract.^{15,21} Mean survival of 1.7 years with a 60% mortality rate within 3 years was reported.^{22,23} These are locally aggressive tumors, and locoregional control is therefore the main aim of treatment.³ Most of the literature reported a 89% incidence in males and 11% in females.²⁻¹⁵ The rapid growth and extensive local destruction hinders early diagnosis. Diagnosis is made by the presence of immature neural tissue and fetal epithelial structure admixed with various malignant and mesenchymal elements.^{3,11-14,21-24}

An origin from a primitive neural crest or stem or progenitor cell with multidirectional differentiation is currently favored.^{14,20,24} Local recurrence after surgery was

seen in 30 to 43%, hence, adjuvant treatment is recommended in the form of radiation and chemotherapy.^{6,7} As the tumor is highly aggressive and rare no adequate radiotherapy doses are described and individualization of therapy should be considered.^{13,14} The complex tumor shape and close proximity to critical structures has made 3D CRT and IMRT better in delivering higher radiation doses to the target volumes.³ Cervical node metastasis are seen in 17% and no elective neck dissection is indicated.³ Longer disease free survival in some patients after wide excision surgery has made imaging based assessment of tumor stage and respectability more important.^{3,6} All the three large case series reported so far report a 2-year survival rate of 40 to 46% and an average survival rate of 1.7 to 2 years.^{3,6}

CONCLUSION

Sinonasal teratocarcinoma has a proven poor prognosis with locoregional recurrence. The disease free survival rate is nearly 28% and overall survival rate of 46%. Optimal resection margins are to be defined and multimodality treatment in the form of postoperative radiotherapy and chemotherapy are to be standardized.

REFERENCES

1. Shanmugaratnam K. International histological classification of tumors. Berlin, Germany: Springer-Verlag 1991:70-71.
2. Redondo Martinez E, Rey Lopez A, Reguera Parra V, Bolanos Rodriguez C. Sinusal teratocarcinoma. Acta Otorrinolaringol Esp 1991;42(5):363-67.
3. Budrukkar A, Agarwal JP, Kane S, Siddha M, Laskar SG, Pai P, et al. Management and clinical outcome of sinonasal teratocarcinoma: Single institution experience. J Laryngol Otol 2010;124:739-43.
4. Heffner DK, Hyams VJ. Teratocarcinoma (malignant teratoma?) of the nasal cavity and paranasal sinuses. A clinicopathologic study of 20 cases. Cancer 1984;53:2140-54.
5. Pai SA, Naresh KN, Masih K, Ramarao C, Borges AM, Path FRC. Teratocarcinoma of the paranasal sinuses: A clinicopathologic and immunohistochemical study. Hum Pathol 1998;29:718-22.
6. Smith SL, Hessel AC, Luna MA, Malpica A, Rosenthal DI, El-Naggar AK. Sinonasal teratocarcinoma of the head and neck: A report of 10 patients treated at a single institution and comparison with reported series. Arch Otolaryngol Head Neck Surg 2008;134:592-95.
7. Sharma HS, Abdullah JM, Othman NH, Muhamad M. Teratocarcinoma of the nasal cavity and ethmoid. J Laryngol Otol 1998;112:682-86.
8. Fernandez PL, Cardesa A, Alos L, Pinto J, Traserra J. Sinonasal teratocarcinoma: An unusual neoplasm. Pathol Res Pract 1995;191(2):166-71.
9. Prasad KC, Pai RR, Padmanabhan K, Chawla S. Teratocarcinoma of the nose, paranasal sinuses and nasopharynx. J Laryngol Otol 2003;117(4):321-24.
10. Shemen L, Galantich P, Murali R. Malignant teratocarcinoma of the sphenoid sinus. Otolaryngol Head Neck Surg 1995;112(3):496-500.

11. Fukuoka K, Hirokawa M, Shimizu M, et al. Teratocarcinoma of the nasal cavity: Report of a case showing favorable prognosis. *APMIS* 2000;108(9):553-57.
12. Chao KK, Eng TY, Barnes J, Dahiya R. Sinonasal teratocarcinoma. *Am J Clin Oncol* 2004;27(1):29-32.
13. Terasaka S, Medary MB, Whiting DM, Fukushima T, Espejo EJ, Nathan G. Prolonged survival in a patient with sinonasal teratocarcinoma with cranial extension. Case report. *J Neurosurg* 1998;88(4):753-56.
14. Batsakis JG, El-Naggar AK, Luna MA. Teratomas of the head and neck with emphasis on malignancy. *Ann Otol Rhinol Laryngol* 1995;104(6):496-500.
15. Tchoyoson Lim CC, Thiagarajan A, Sim CS, Khoo ML, Shakespeare TP, Ng I. Craniospinal dissemination in teratocarcinoma. *J Neurosurg* 2008;109(2):321-24.
16. Wei S, Carroll W, Lazenby A, Bell W, Lopez R, Said-Al-Naief N. Sinonasal teratocarcinoma: Report of a case with review of literature and treatment outcome. *Ann Diagn Pathol* 2008;12(6):415-25.
17. Shindo ML, Stanley RB Jr, Kiyabu MT. Carcinosarcoma of the nasal cavity and paranasal sinuses. *Head Neck* 1990;12(6):516-19.
18. Christensen E, Fu Y, Wilson L, Hoover L. Teratoid carcinosarcoma of the nasal and paranasal cavities: A case report. *Am J Rhinol* 1992;6(5):169-72.
19. Devgan BK, Devgan M, Gross CW. Teratocarcinoma of the ethmoid sinus: Review of literature plus a new case report. *Otolaryngology* 1978;86(5):689-95.
20. Endo H, Hirose T, Kuwamura KI, Sano T. Case report: Sinonasal teratocarcinoma. *Pathol Int* 2001;51(2):107-12.
21. Carrizo F, Pineda-Daboin K, Neto AG, Luna MA. Pharyngeal teratocarcinoma: Review of the literature and report of two cases. *Ann Diagn Pathol* 2006;10(6):339-42.
22. Szudek J, Bullock M, Taylor SM. Sinonasal teratocarcinoma involving the cavernous sinus. *J Otolaryngol* 2005;34(4):286-88.
23. Shorter C, Nourbakhsh A, Dean M, Thomas-Ogunniyi J, Lian TS, Guthikonda B. Intracerebral metastasis of a sinonasal teratocarcinoma: A case report. *Skull Base* 2010;20(5):393-96.
24. Kleinschmidt-DeMasters BK, Pflaumer S, Mulgrew T, Lillehei K. Sinonasal teratocarcinoma (mixed olfactory neuroblastoma—craniopharyngioma) presenting with syndrome of inappropriate secretion of antidiuretic hormone. *Clin Neuropathol* 2000;19(2):63-69.

ABOUT THE AUTHORS

Sudhir M Naik (Corresponding Author)

Fellow, Department of Head and Neck Oncosurgery, Kidwai Memorial Institute of Oncology, Bengaluru, Karnataka, India, Phone: 09916807109, e-mail: sud223@gmail.com

Nanjundappa

Professor, Department of Head and Neck Oncosurgery, Kidwai Memorial Institute of Oncology, Bengaluru, Karnataka, India

Rajshekar Halkud

Associate Professor, Department of Head and Neck Oncosurgery, Kidwai Memorial Institute of Oncology, Bengaluru, Karnataka, India

Srihariprasad

RMO, Department of Head and Neck Oncosurgery, Kidwai Memorial Institute of Oncology, Bengaluru, Karnataka, India

K Sidappa

Assistant Professor, Department of Head and Neck Oncosurgery, Kidwai Memorial Institute of Oncology, Bengaluru, Karnataka, India

Sumit Gupta

Fellow, Department of Head and Neck Oncosurgery, Kidwai Memorial Institute of Oncology, Bengaluru, Karnataka, India

Clementina Rama Rao

Professor, Department of Pathology, Kidwai Memorial Institute of Oncology, Bengaluru, Karnataka, India