

# Computerized Tomography of Paranasal Sinuses: A Roadmap to Endoscopic Surgery

Ashok K Gupta, Bhumika Gupta, Neha Gupta, Nishikanta Tripathi

## ABSTRACT

A detailed knowledge of sinonasal anatomy is a prerequisite for safe and successful surgery. Variation in the key landmarks of sinonasal anatomy was recorded in this study both on radiology and during surgery. These variations are especially important while working near optic nerve because a single wrong step during surgery can lead to visual loss.

**Keywords:** Endoscopic sinus surgery, Sinonasal anatomy, Optic nerve.

**How to cite this article:** Gupta AK, Gupta B, Gupta N, Tripathi N. Computerized Tomography of Paranasal Sinuses: A Roadmap to Endoscopic Surgery. *Clin Rhinol Int J* 2012;5(1):1-10.

**Source of support:** Nil

**Conflict of interest:** None declared

## INTRODUCTION

The changing scenario of indications for endoscopic sinus surgeries; detailed knowledge of sinonasal anatomy is of paramount importance. It is especially important in optic nerve and orbital lesions where vision is at stake. Radiological investigations and image-guided systems do provide help but they can no way replace surgeon's thorough anatomical knowledge to perform a safe and successful surgery. Various cadaveric and radiological studies have been done to know about the important landmarks and anatomical variations. Llyod et al<sup>3</sup> in 1991 reported the usefulness of computed tomography in preoperative evaluation before functional endoscopic sinus surgery (FESS). Sahni et al<sup>13</sup> in 2009 described various anatomical variations in a cadaveric study.

High resolution CT scanning of PNS provides excellent bony detail and soft tissue mapping. Axial and coronal views are obtained with the head in neutral position and hyperextension respectively. CT has become the modality of choice for inflammatory disease of the sinuses and the ostiomeatal complex. It provides various anatomic landmarks at the skull base. Limited resections of inflammatory tissue or anatomic obstruction along normal drainage channels of the sinuses reestablish mucociliary clearance of the sinuses. High resolution CT evaluates the extent of the inflammatory disease and assesses important anatomic landmarks and their variations. Anatomy of the sinonasal passages have many variations; some of which are seen more frequently in patients with chronic sinonasal inflammation. These variants include nasal septal deviation,

septal spurs, paradoxical middle turbinate, concha bullosa, Haller cells, and abnormal deviation of the uncinat process. These variations can result in narrowing of the infundibulum or the maxillary ostium. Presence of Onodi cells, low placed fovea ethmoidalis, are some 'dangerous' normal variations that should be recognized before FESS to avoid risk of injury.

As the use of endoscopy for the evaluation and surgical treatment of paranasal sinus diseases is increasing, attention is now being directed toward the anatomy of the lateral nasal wall and paranasal sinus. Nose and paranasal sinus (PNS) computed tomography (CT) has become a widely accepted tool for providing detailed anatomy of PNS. To avoid complications during endoscopic sinus surgery CT scan should be studied thoroughly before surgery.

Not much is available in English literature about the anatomical variations in North Indian population. So this study aims at the provision of data regarding the anatomical variations to the budding ENT surgeons, so that overall complication rate is decreased.

## MATERIALS AND METHODS

Our institute is a tertiary center which largely caters the North Indian population. This was a prospective and non randomized study conducted at the Department of Otolaryngology and Head and Neck Surgery, Postgraduate Institute of Medical Education and Research at Chandigarh from September 2010 to December 2011. Initially a cadaveric study was conducted to know about the anatomical variations of paranasal sinuses in North Indian population and their percentage were recorded. Then endoscopic surgery was performed on a total of 69 patients for diseases of nose and paranasal sinuses. Preoperative evaluation included detailed history and examination of nose and paranasal sinuses. Then a noncontrast computed tomography of nose and PNS was done and was studied in detail for various anatomical variations. Scan protocols included:

- Slice thickness was kept 3 mm
- Scans were taken in all three planes—axial, coronal, sagittal
- Both soft tissue and bone windows were studied
- Scans were studied in a systematic way.

The findings were noted in a performa and then enclosed in an envelope and later on compared after findings on endoscopic sinus surgery. Various diseases, for which FESS

was performed, included chronic sinusitis, nasal polyposis, allergic fungal rhinosinusitis, optic nerve decompression, orbital decompression and optic nerve decompression. A total of 138 sides were examined. Anatomical variations which were studied; included deviated nasal septum (DNS), inferior turbinate hypertrophy (ITH), concha bullosa, paradoxical and duplicated middle turbinate (MT), fenestrated uncinata process (UP), maxillary septa and hypoplasia, types of frontal cell, type of olfactory fossa, Onodi cells and type of optic nerve. Some of these variables noted on scan were then compared endoscopically. Some of the parameters like septal pneumatization, pneumatized crista galli and clinoid process, and pterygoid pneumatization were not explored endoscopically but studied only radiologically. A special importance was given to the variations in course of optic nerve in relation to sphenoid sinus and Onodi cell whenever later was present.

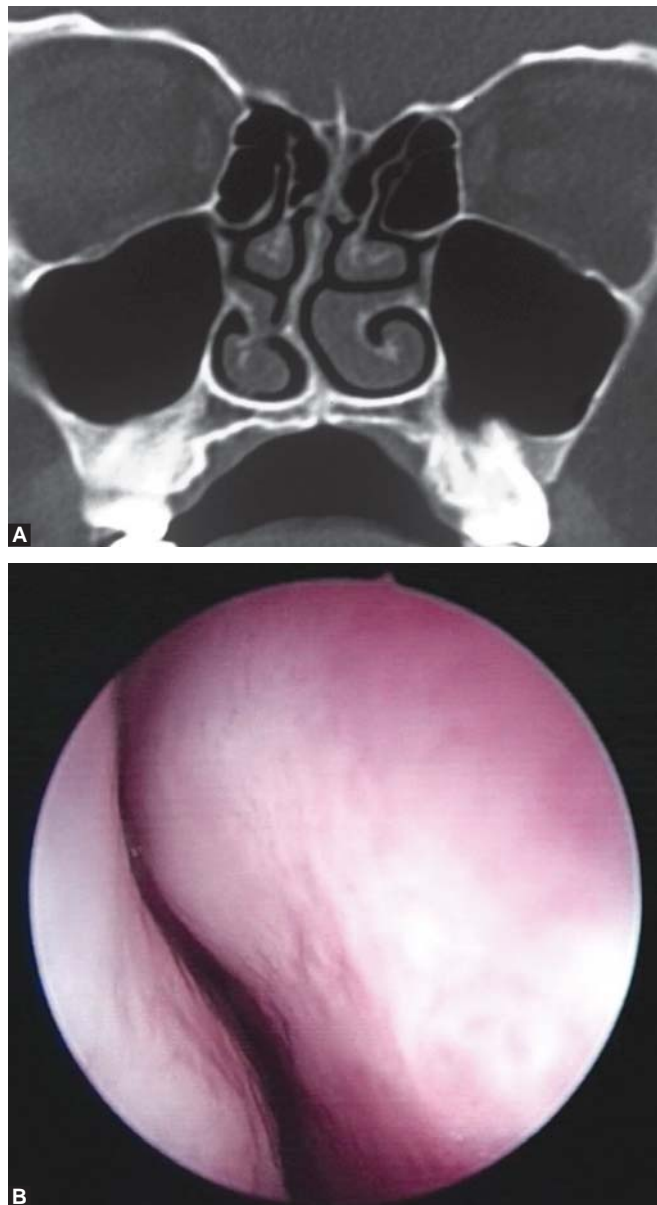
Data was then analyzed and percentage of different variation both on CT scan and during surgery were calculated. Sensitivity and specificity of CT scan for some of the variations were also recorded.

## RESULTS

A total of 69 patients were included in this study and total 138 sides were examined. Sixty-eight percent were males; 32% were females. Most common age group was between 20 to 45 years. DNS (Figs 1A and B) was seen in 45 (65.2%) patients in CT scan while intraoperatively it was found in 50 (72.4%) patients. Sensitivity of CT scan in detecting DNS was 90% while specificity was 100%. Inferior turbinate (ITH) was found in 15 (10.8%) on CT scan but during surgery only 14 (10.1%) sides had ITH. One patient (0.72%) had osteitis of inferior turbinate due to disease process. Sensitivity for detection of ITH was found to be 100%.

Concha bullosa (Figs 2A and B) was seen in 16 (11.5%) sides both on scanning and during surgery. One patient had bilateral concha bullosa (Fig. 3). Conchal pneumatization was found to be more common (68%) than the lamellar pneumatization (32%). Sensitivity and specificity of CT scan in detecting concha was 100%. Paradoxical MT (Fig. 4) was found on two (1.44%) patients on CT but incidence was more during surgery nine (13.04%). Sensitivity of CT in detection of paradoxical MT is only 22.22%. Other variations of MT which were recorded intraoperatively were duplicated in two (1.44%); multilobulated MT in one (0.72%); accessory MT in one (0.72%) and bifid MT in one (0.72%) side.

Among the variations of uncinata process (UP); fenestrated UP was seen in one (1.44%) patient; ballooned



**Figs 1A and B:** Deviated nasal septum

out UP (Fig. 5) in three (4.34%) patients; and in one patient (1.44%) UP was attached to lamina papyracea. All of UP variations were seen intraoperatively. Maxillary sinus septa (Fig. 6) were present in three (2.1%) sides. Agger nasi cells were seen in 95 (68.8%) sides.

Anterior ethmoidal artery (AEA) (Figs 7A and B) was seen in seven (5.07%) CT scans but intraoperatively it was found in 45 (32.60%) sides. In one of the patient the course of AEA was very tortuous without a bony canal. Sensitivity of CT for AEA is only 15.5%. None of the CT was able to show posterior ethmoidal artery but intraoperatively it was seen in two (2.89%) patients. Superior turbinate was seen in 18 (13.04%) sides in CT scan but intraoperatively seen in 76 (55.07%) sides. Sensitivity of detecting superior turbinate on CT is 23.68%.

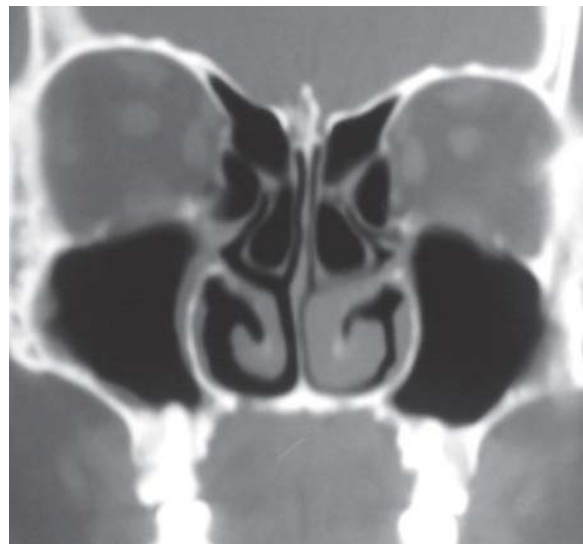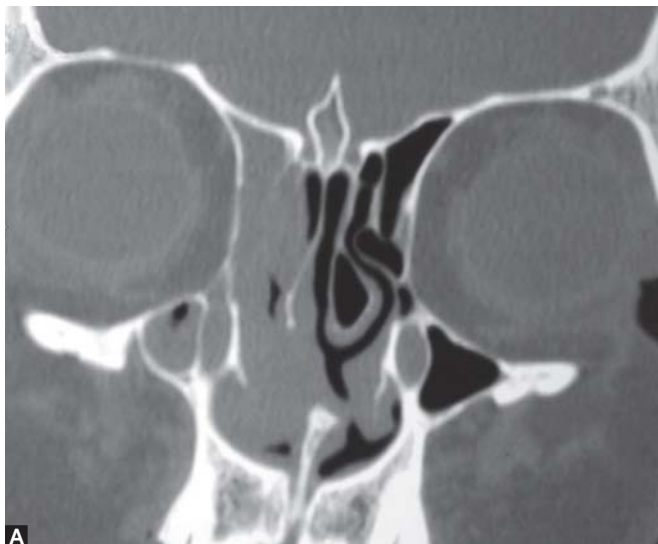
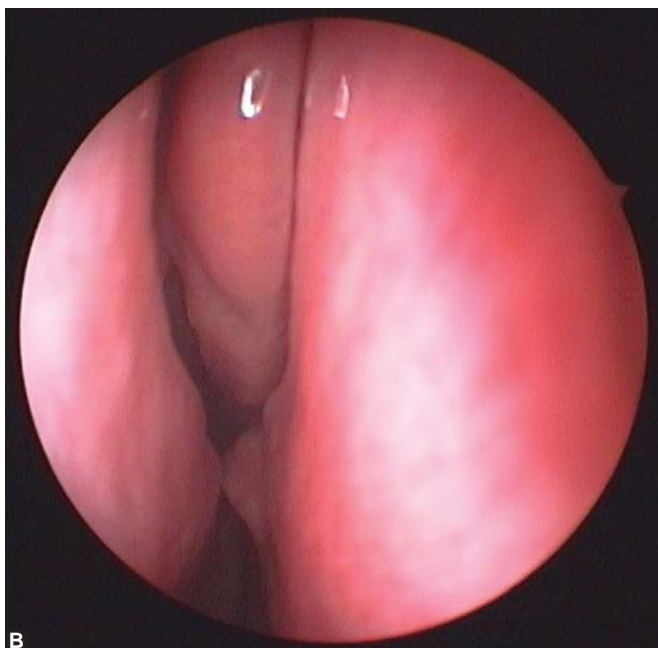


Fig. 3: Bilateral concha bullosa



Figs 2A and B: Concha bullosa

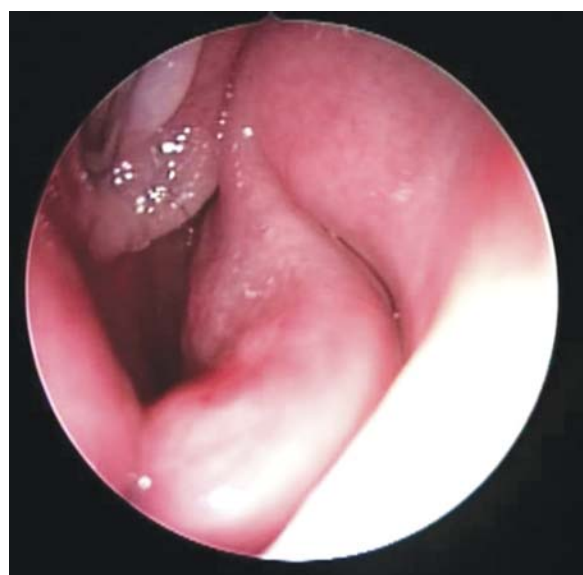

Fig. 4: Pardonical middle turbinate

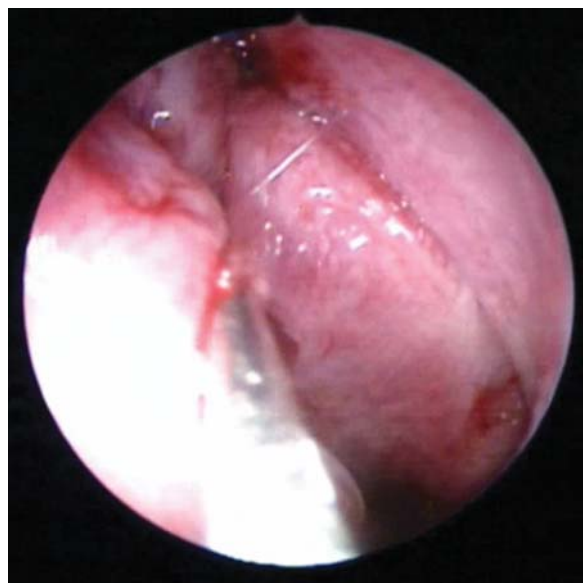

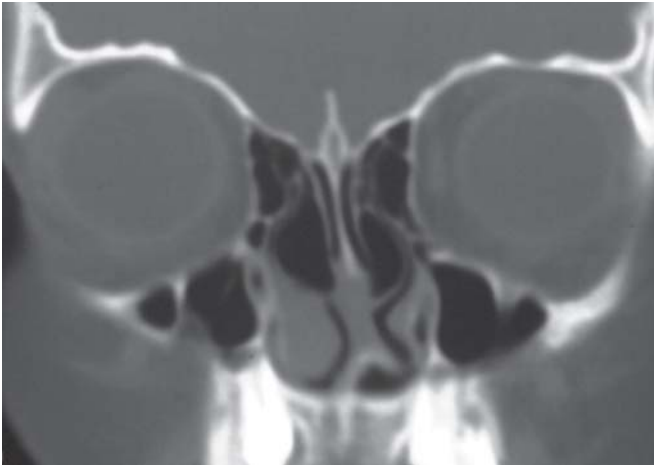
Fig. 5: Ballooned out uncinata process

Septal pneumatization (Fig. 8) was seen in nine (13.04%) patients; pneumatized crista galli in 23 (33.33%); pterygoid pneumatization (Fig. 9) in nine (13.04%); and pneumatized clinoid process in one (1.44%) patient. Haller cell was seen in five (3.62%) sides. One (1.44%) had atelectatic infundibulum. None of the patients showed carotid or optic nerve dehiscence in our study.

Thirty-three patients (47.82%) had Onodi cell (Figs 10A and B). There was one patient who had bilateral Onodi cells.

Single intrasphenoid septum (Figs 11A to C) was seen in 34 (24.6%) sides. Multiple intrasphenoid septa were seen in 17 (12.3%) sides on CT scan but intraoperatively found in 21 (15.21%) sides. Intrasphenoid septa were attached to optic nerve in 3% of sides and to carotid artery in 2% of sides.





**Fig. 6:** Maxillary sinus septa

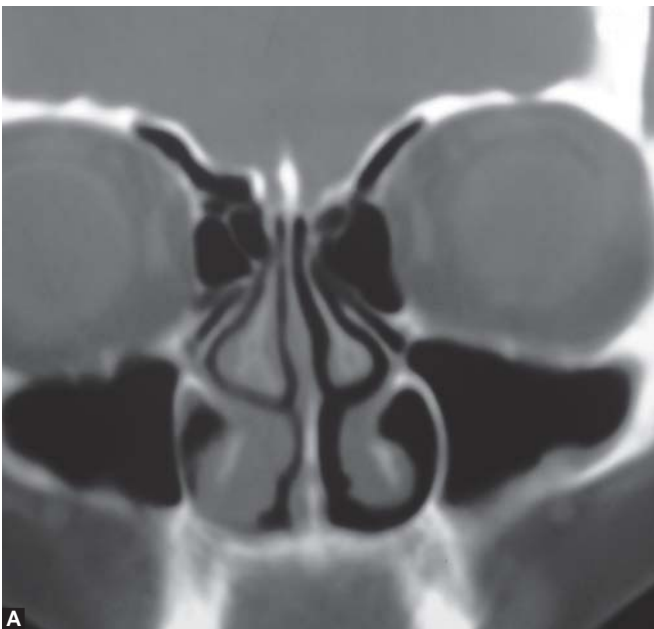Type I optic nerve (Fig. 12) was seen in 89 (64.49%) sides; type II (Fig. 13) in 36 (21.30%); type III in 3 (4.37%) and type IV (Fig. 14) in 10 (14.49%) (Pie chart 1).

Regarding olfactory fossa; 69 (50%) sides had Kero's type I (Fig. 15); 65 (47.10%) had type II (Fig. 16); and four (2.89%) had type III olfactory fossa (Fig. 17). One patient had type I OF on one side and type II on the other side (Pie chart 2).

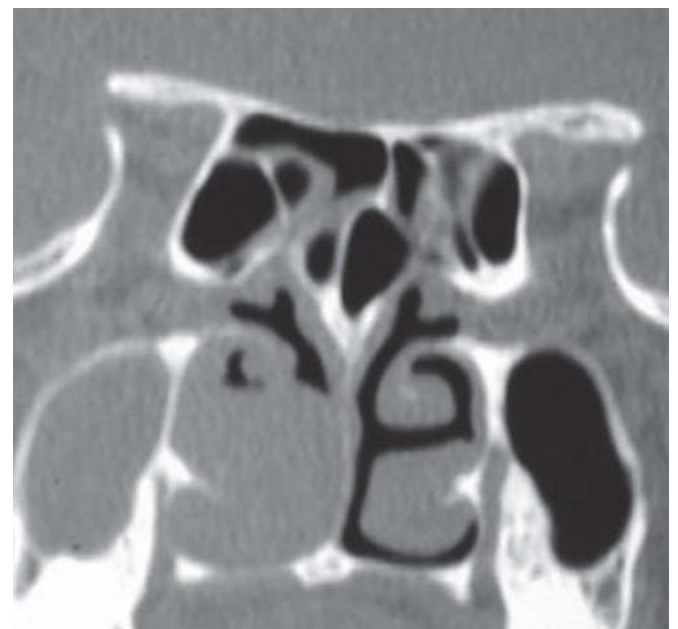
Bent and Kuhn frontal cell configuration in our study was as follows (Table 1):

Dehiscent carotid artery was seen in one (1.44%) patient.

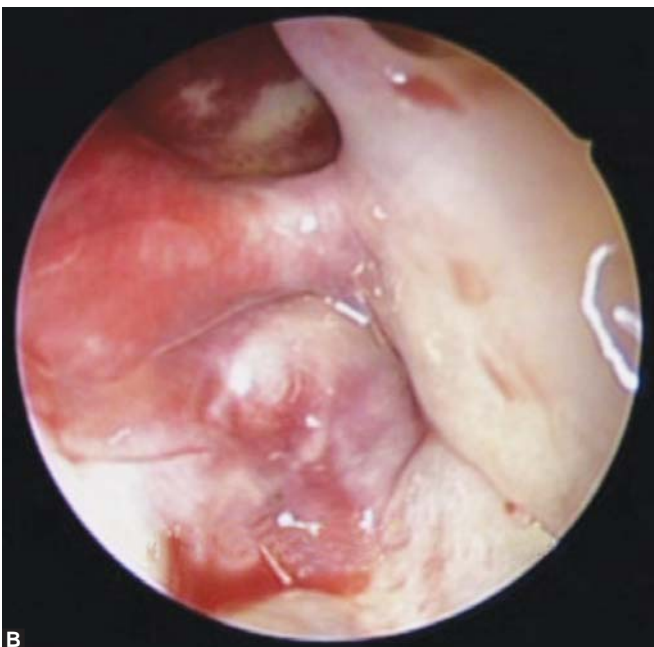Dehiscent optic nerve (Fig. 20) was seen in two (2.89%) patients.



**A**

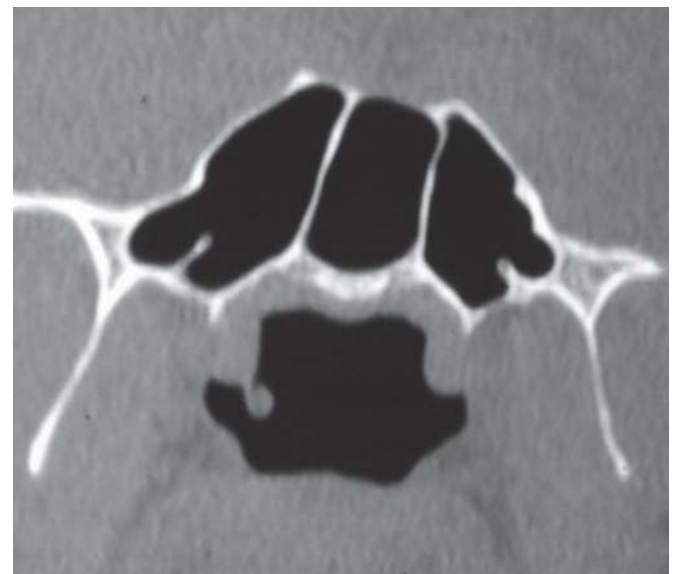


**Fig. 8:** Septal pneumatization

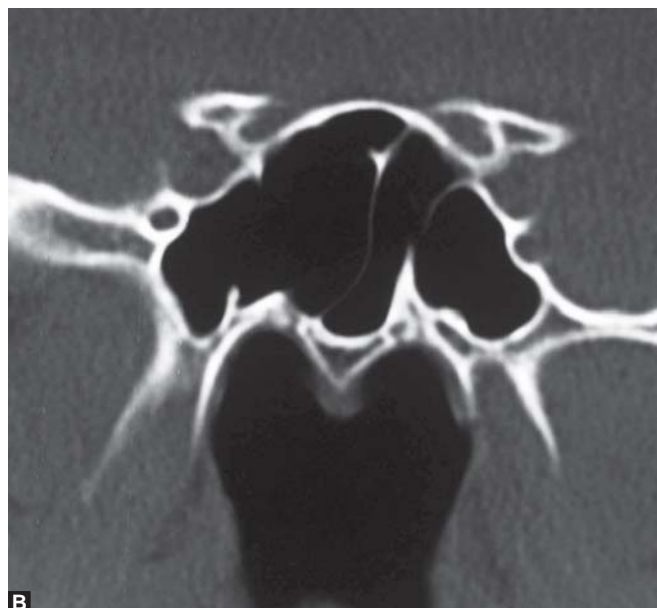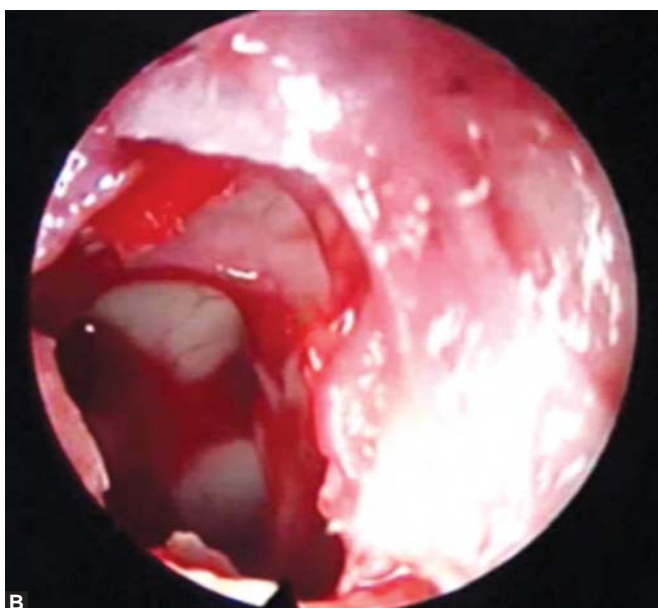
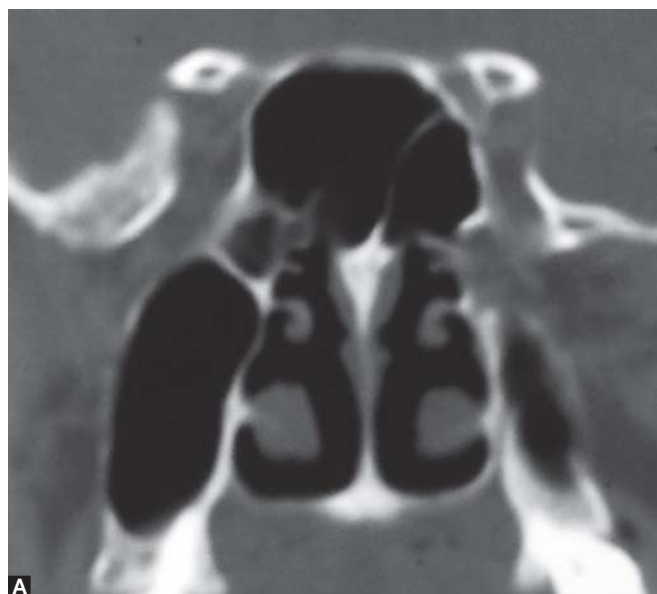
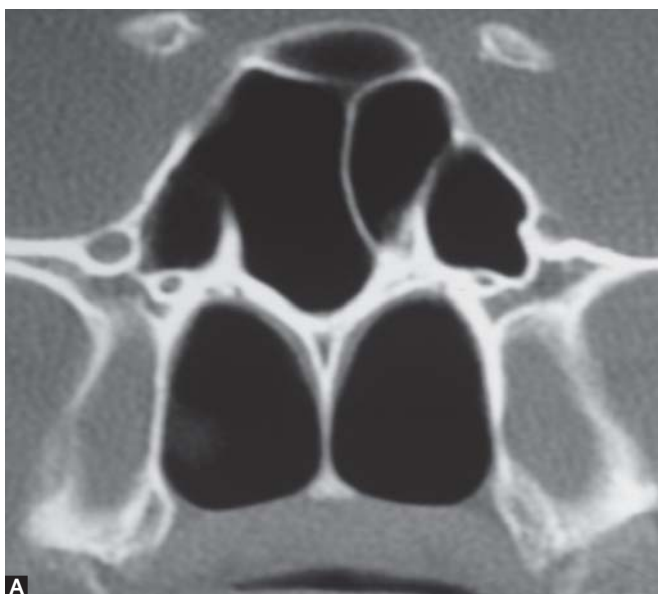


**B**

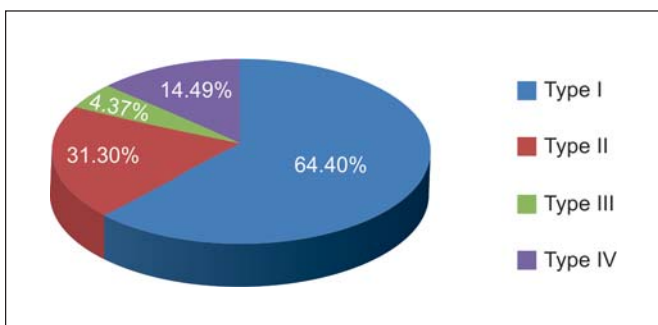
**Figs 7A and B:** Anterior ethmoidal artery



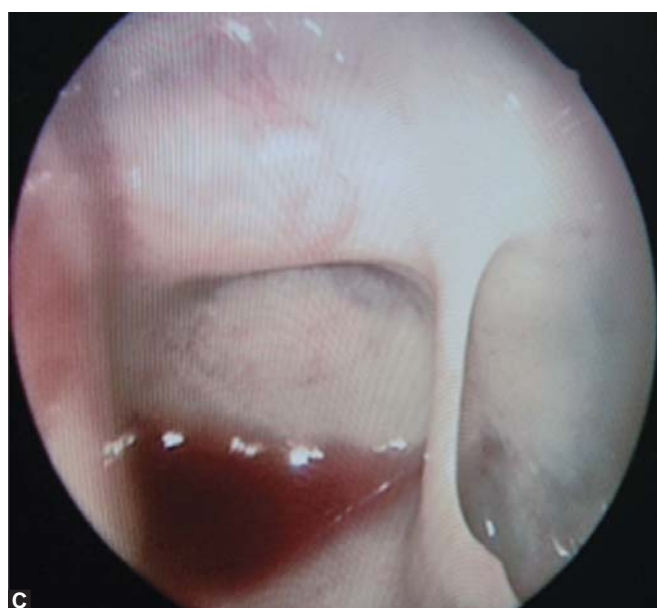**Fig. 9:** Pterygoid pneumatization



Figs 10A and B: Onodi cell



Pie Chart 1: Type of optic nerve



Figs 11A to C: Intersphenoid septa

**DISCUSSION**

CT scan of paranasal sinuses remains the investigation of choice for all patients undergoing functional endoscopic

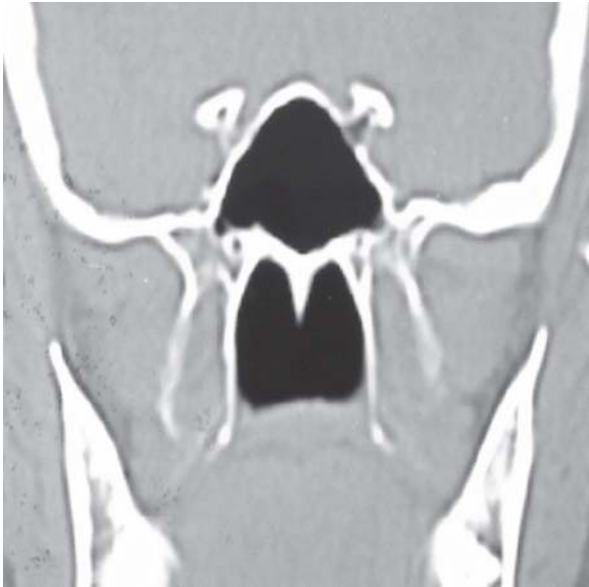


Fig. 12: Type I optic nerve

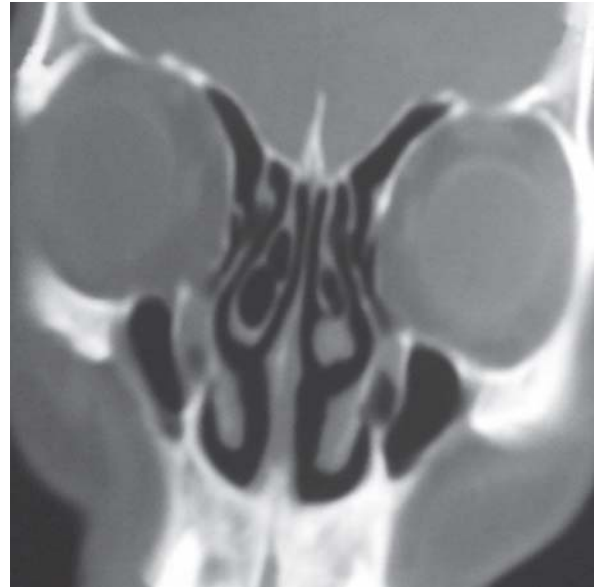

Fig. 15: Type I olfactory fossa

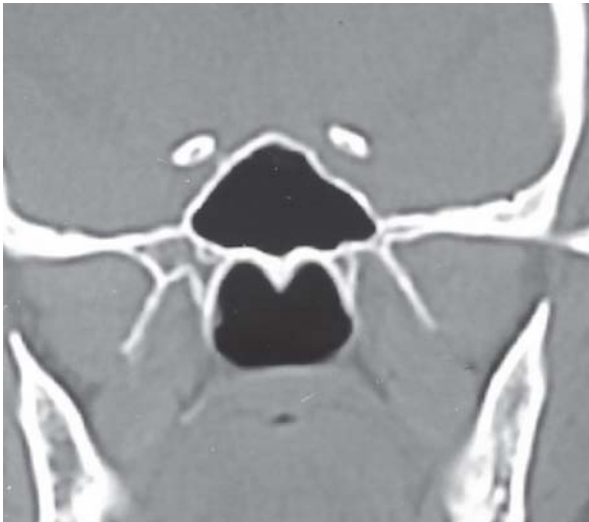

Fig. 13: Type II optic nerve

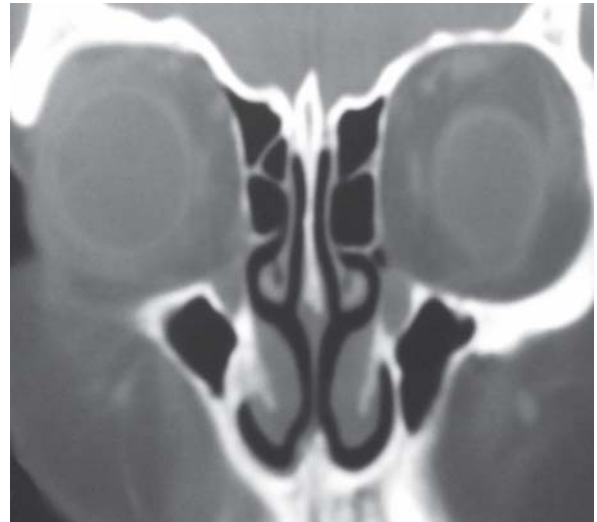

Fig. 16: Type II olfactory fossa

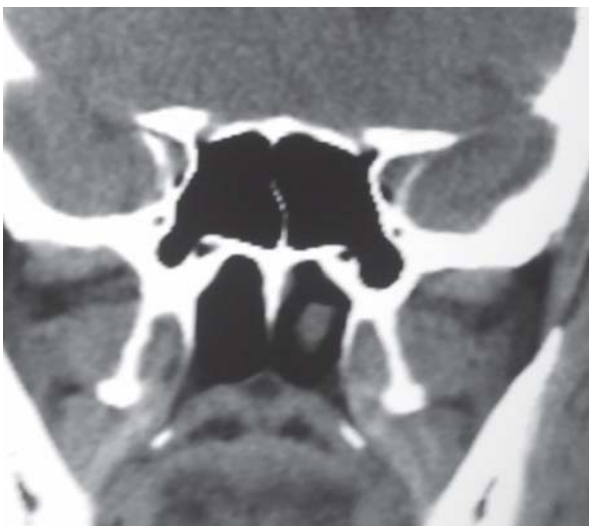

Fig. 14: Type IV optic nerve

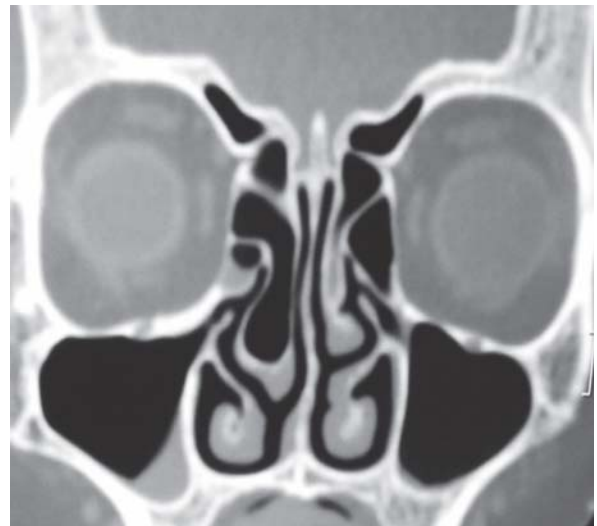
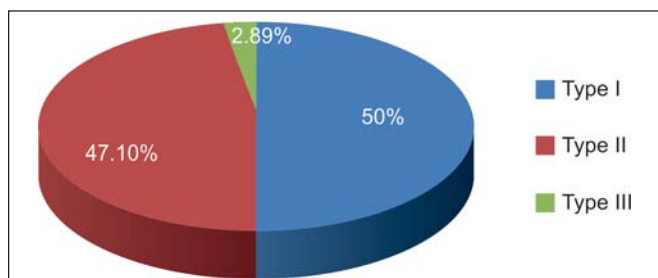


Fig. 17: Type III olfactory fossa





Pie Chart 2: Type of olfactory fossa

Table 1: Type of frontal cell

Type of frontal cell	Number of sides	Percentage
Type I (Fig. 18)	25	18.11
Type II	3	2.17
Type III	6	4.34
Type IV (Fig. 19)	6	4.34

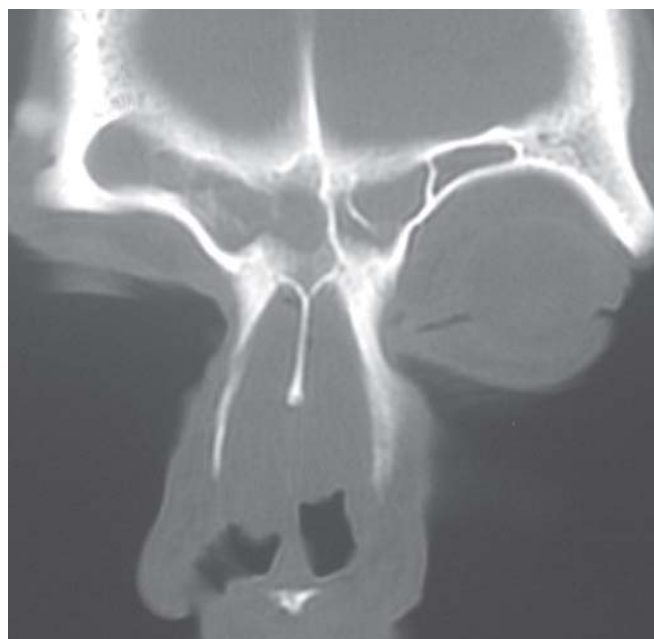


Fig. 19: Type IV frontal cell

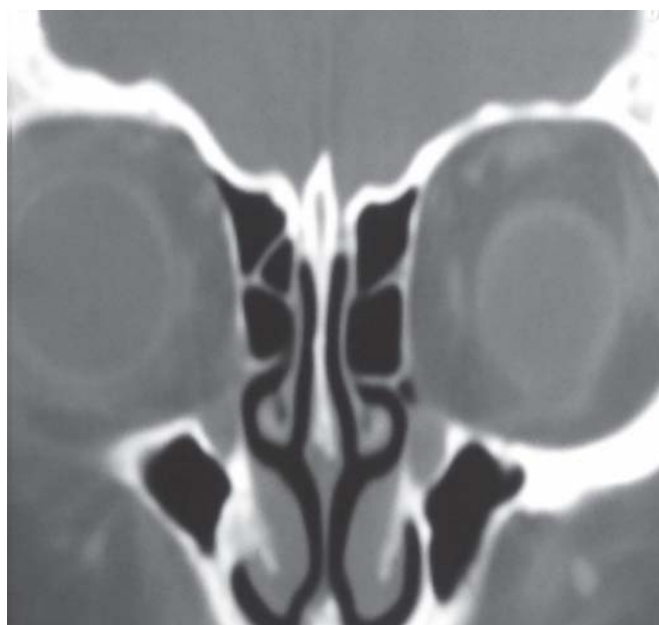


Fig. 18: Type I frontal cell

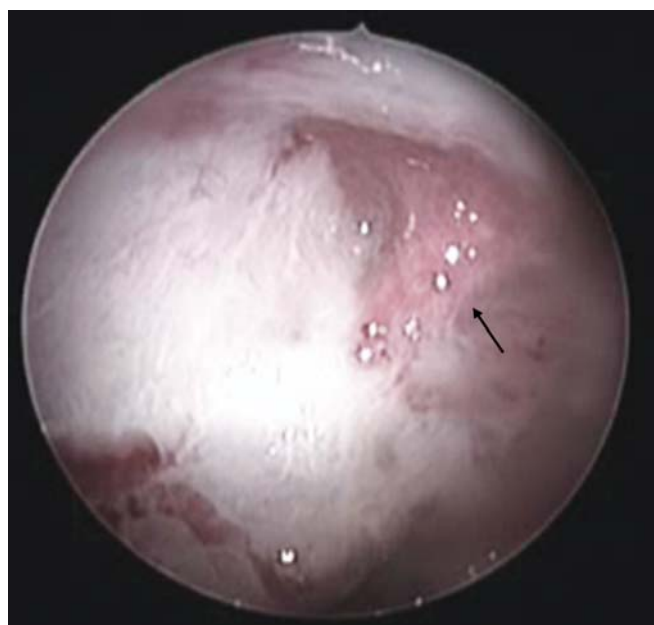


Fig. 20: Dehiscent optic nerve

sinus surgery because it provides a road map on for surgeon. It depicts the anatomical variations of PNS in a much simpler way and helps the surgeon in preventing untoward complication during surgery. It requires a coordination between radiologist and endoscopic surgeon so that all the anatomical variations can be seen preoperatively and thus intraoperative complications can be reduced. Endoscopic surgery should be performed in a stepwise manner enabling the journey of endoscopic surgeon safe.

One of the common anatomical variations is deviated nasal septum which can predispose to sinusitis. A simple correction of deviated septum can cause reversal of features of sinusitis. At times it can predispose to recurrent epistaxis which makes the examination difficult. In our study this was the commonest anatomical variations seen in 65.2% CT scans but intraoperatively it was seen in 72.4%. The sensitivity of CT in detection of DNS is 90%. A study by K Dua et al<sup>10</sup> and Earwaker<sup>5</sup> showed a much less incidence of DNS, i.e. 44%. A cadaveric study by Daisy S et al<sup>13</sup>

reported an incidence of 70% which is comparable to the present study.

Inferior turbinate hypertrophy (ITH) can be a compensatory process or a infectious pathology. A preoperative preparation with steroid nasal spray and decongestants helps to reduce the inflammation and thus a good working space. In our study; ITH was seen in 10.8% cases on both CT and endoscopic surgery with a sensitivity of 100% for CT scan.

Concha bullosa is abnormal pneumatization of middle turbinate which may block the infundibulum and may lead to sinus disease due to defective aeration of the sinuses. Concha bullosa was seen in 11.55% of sides in our study which is less as compared to the reported incidence of 53.6% by Bolger et al,<sup>2</sup> 42.6% by Maru et al,<sup>8</sup> 28% by Asruddin et al,<sup>7</sup> 24% by Llyod<sup>3</sup> and 25% in cadaveric study by Daisy S et al.<sup>13</sup> The incidence of concha bullosa was 16% in a study by K Dua et al<sup>10</sup> and 14% by Llyod et al<sup>1</sup> which is comparable to our study. Concha bullosa was seen in 35 and 42% of the patients on the right and left sides respectively in a study by Sheetal et al.<sup>8</sup> Other variations related to middle turbinate are duplication of middle turbinate in 0.72%; paradoxical MT in 13.04%; duplication of MT one (0.72%) on CT; two (1.44%) intraoperatively; multilobulated MT in 0.72%; accessory MT in 0.72% and bifid MT in 0.72% sides. In a study by Earwaker<sup>5</sup> incidence of paradoxical MT was seen in 23.6% (379 sides). In cadaveric study by Daisy S et al<sup>13</sup> incidence of paradoxical MT is 15% which is comparable to our study. Paradoxical MT is the abnormal curvature of MT where the convex surface faces laterally and may block the drainage pathway of middle meatus.

Attachment of uncinate process is known to have a bearing on the drainage of frontal sinus. If it is attached to lamina papyracea; frontal sinus drains medial to UP but if it is attached to skull base or MT; then sinus drains into infundibulum just lateral to UP. One should be aware of presence of accessory ostium because during surgery, if the natural and accessory ostia are not joined then it can lead to recirculation phenomenon with persistent symptoms.

Maxillary sinus septa in Earwaker<sup>5</sup> study is in 19 (2.3%) patients while in our study it was seen in three (2.1%) patients and is comparable to study by Earwaker.

Agger nasi cells are the anterior most anterior ethmoid air cells. Agger nasi cells may narrow the frontal recess and obstruct the lower end of the frontonasal duct leading to frontal sinus disease. Agger nasi cells were seen in 68.8% sides in the present study which is less as compared to study by Benjaporn Nitinavakarn et al (92.1%);<sup>11</sup> Bolger et al (89%);<sup>2</sup> Earwaker (96%).<sup>5</sup> Llyod et al<sup>3</sup> reported a much less

incidence of agger nasi cells (14%). Cadaveric study by Daisy S et al<sup>13</sup> showed agger nasi cells in 80% specimens.

Presence of various types of frontal cells may change the drainage pathway of frontal sinus. They should be studied in detail on CT scan preoperatively and all cells must be opened during surgery to achieve an adequate frontal sinusotomy and for complete removal of disease. Presence of a midline lesion in frontal sinus requires a modified Lothrop's procedure. If any type of frontal cell is present; all of them should be opened to reach up to frontal sinus. About the findings in frontal sinus; it was absent on one side in one (0.72%) patient. Type I frontal cell was seen in 25 (18.11%) sides; type II in three (2.17%); type III in six (4.34%) sides; and type IV in six (4.34%) sides. Aplastic frontal sinus was seen in 5% patients in study by Earwaker;<sup>5</sup> in 21 sides (11.9%) study by Benjaporn Nitinavakarn et al<sup>11</sup> and in 6.06% in study by Pongsakorn Tantilipikorn et al.<sup>12</sup> The prevalence of frontal cells in the study by Pongsakorn Tantilipikorn et al<sup>12</sup> was 20.08% for type I; 4.92% for type II; 3.79% for type III; and 1.39% for type IV.

Anterior ethmoidal artery (AEA) is located in roof of anterior ethmoids posterior to frontal recess and may lie in a bony canal or in a bony mesentery. It can be visualized on coronal sections on CT scan where it forms medial beak of superomedial orbital wall as it branches out from ophthalmic artery. It was seen in seven (5.07%) CT scans but intraoperatively it is found in 45 (32.60%) sides in the present study; sensitivity of scan being only 15.5%. Knowledge of course of AEA is very important for surgeon. If injured during surgery, it gets retracted into the orbit causing orbital hematoma and subsequent visual loss if not treated immediately. So surgeon must be familiar with the possibility of an abnormal course of AEA.

Haller cells are anterior ethmoid cells that grow into the floor of orbit and may narrow the ostium of the maxillary sinus which is likely to occur if these cells become infected. Haller cells are seen in 3.62% (5) sides in the present study which is much less as compared to 28.5% (228 sides) in study by Earwaker;<sup>5</sup> 23.8% sides by Benjaporn Nitinavakarn et al;<sup>11</sup> and 15% by Llyod et al.<sup>3</sup> Haller's cells were present in 2 and 4% of the patients on the right and left sides respectively in study by Sheetal et al<sup>14</sup> which is comparable to our study.

Kero's has described three type of olfactory fossa depending on the depth; type I 1 to 3 mm; type II 4 to 7 mm; and type III > 8 mm. More is the depth; more is the chances of injury to skull base during FESS. Sixty-nine (50%) sides had Kero's type I; 65 (47.10%) had type II; and four (2.89%) had type III olfactory fossa in the present study. In study by



Benjaporn Nitinavakarn et al<sup>11</sup> type I was seen in 11.9%; type II in 68.8%; and type III in 19.3%. Asymmetrical depth was seen in one patient (1.44%) which is less as reported in study by Benjaporn Nitinavakarn et al<sup>11</sup> (27 patients). Kero's type II was the commonest type (77%) of olfactory fossa, followed by type I (20%) in study by Sheetal et al.<sup>14</sup>

The posterior ethmoid cells may extend into sphenoid sinus and may surround the optic nerve. These cells are called Onodi cells. Their presence may increase the chances of optic nerve injury. Onodi cells were seen in 47.82% sides in our study. One patient had bilateral Onodi cell. In study by Dua et al<sup>10</sup> Onodi cells were seen in 6% of patients; by Jones<sup>9</sup> in 4% patients; by Earwaker<sup>5</sup> in 24% of patients; by Arslan et al<sup>6</sup> in 12%; by Kainz et al<sup>4</sup> in 42% and by Benjaporn Nitinavakarn et al<sup>11</sup> in 25% sides. Daisy S et al<sup>13</sup> reported Onodi cells in 10% of cadavers. Generally, in presence of Onodi cell optic nerve passes through the cell but in our study we have seen that it was not true all the time. In some cases it passes from sphenoid sinus. With increasing number of optic nerve fenestration for benign intracranial hypertension; knowledge of variations in the course of optic nerve has become very important. Also; a preoperative knowledge of attachment of sphenoid septa can reduce complications as they can be attached to optic nerve or carotid artery. In our study 3% of intrasphenoid septa were found to be attached to optic nerve and 2% were found to be attached to carotid artery.

Septal pneumatization was seen in nine (13.04%) patients; pneumatized crista galli in 23 (33.33%); pterygoid pneumatization in nine (13.04%); and pneumatized clinoid process in one (1.44%) patients. In study by Earwaker<sup>5</sup> septal pneumatization was seen in 25% of cases (122 middle of septum and 78 rostral septum); pneumatized crista galli in 7.5%; pterygoid pneumatization in 30% and pneumatized clinoid process in 14%. Bolger et al<sup>3</sup> showed anterior clinoid pneumatization in 13.3% of the patients and pterygoid pneumatization in 43.6% of the cases.

In our study; one (1.44%) patient showed dehiscent carotid artery and two (2.89%) patients had dehiscent optic nerve. A study by Sheetal et al<sup>14</sup> noticed dehiscence in both structures in 2% cases which is comparable to our study. Dehiscent carotid artery was seen in 10.2% sides and dehiscent optic nerve in 18.2% by Benjaporn Nitinavakarn et al<sup>11</sup> and 6 and 4% respectively in study by Josef Kainz et al.<sup>4</sup> Dehiscent carotid artery and optic nerve increases the chances of complications during surgery.

To decrease the complications rate, a detailed study of preoperative CT scan is necessary. Need of the hour is to make a roadmap for surgery by a consensus between

radiologist and endoscopic surgeon to minimizing the overall complication rate.

## CONCLUSION

In the present era of endoscopic sinus surgery; a thorough and intimate knowledge of sinonasal anatomy and its variations is a prerequisite for a successful and safe surgery so that complications can be prevented. To fulfill this purpose budding ENT surgeons need to attend various cadaveric dissection courses and FESS workshops. With increasing horizon of sinus surgery where more of optic nerve and anterior and middle cranial fossa lesions are dealt with endoscopically; surgeon needs to be more familiar with variations of course of optic nerve because even a single millimeter of mistake can deprive patient from vision.

## REFERENCES

1. Lloyd GAS. CT of the paranasal sinuses: Study of a control series in relation to endoscopic sinus surgery *The Journal of Laryngology and Otology* June 1990;104:477-81.
2. Bolger EW, Butzin CA, Parsons DS. Paranasal sinus bony anatomic variations and mucosal abnormalities: CT analysis for endoscopic sinus surgery. *Laryngoscope* 1991;101:56-64.
3. Lloyd GAS, Lund VJ, Scadding GK. Computerised tomography in the preoperative evaluation of functional endoscopic sinus surgery. *Journal of Laryngology and Otology* 1991;105: 181-85.
4. Kainz J, Stammberger H. Danger areas of the posterior rhinobasis an endoscopic and anatomical-surgical study. *Acta Otolaryngol (Stockh)* 1992;112:852-61.
5. John Earwaker. Anatomic variants in sinonasal CT. *Radiographics* 1993;13:381-415.
6. Arslan, Aydinoglu A, Bozkurt M, et al. Anatomic variations of the paranasal sinuses: CT examination for endoscopic sinus surgery. *Auris Nasus Larynx* 1999;26:39-48.
7. Asruddin, Yadav SPS, Yadav RK, Singh J. Low dose CT in chronic sinusitis. *Indian Journal of Otolaryngology and Head Neck Surgery* 2000;52:17-21.
8. Maru YK, Gupta V. Anatomic variations of the bone in sinonasal CT. *Indian Journal of Otolaryngol and Head Neck Surgery* 2001; 53:123-28.
9. Jones NS. CT of the paranasal sinuses: A review of the correlation with clinical, surgical and histopathological findings. *Clin Otolaryngol* 2002; 27: 11-17.
10. Dua K, Chopra H, Khurana AS, Munjal M. CT scan variations in chronic sinusitis. *Indian J Radiol Imaging* 2005;15:315-20.
11. Benjaporn Nitinavakarn, Sanguansak Thanaviratananich, Nilubon Sangsilp. Anatomical variations of the lateral nasal wall and paranasal sinuses: A CT study for endoscopic sinus surgery (ESS) in Thai patients. *J Med Assoc Thai* 2005;88(6): 763-68.
12. Tantilipikorn P, Churojana A, Chiewwit P, Phuttharak W, Lerdlum S, Aeumjaturapat S, et al. The accuracy of limited CT in the evaluation of chronic rhinosinusitis and for endoscopic sinus surgery: A multicenter study. *Siriraj Medical Journal* 2009;61(1):3-7.

13. Sahni D, Mehta R, Aggrawal A, Gupta AK. Towards the understanding of sinonasal anatomical variations: A cadaveric study. *Clinical Rhinology: An International Journal* 2009;2: 37-42.
14. Sheetal D, Devan PP, Manjunath P, Martin P, Satish Kumar K, Sreekantha, Satish TG, et al. CT PNS: Do we really require before fess? *Journal of Clinical and Diagnostic Research* 2011;5(2):179-81.

## ABOUT THE AUTHORS

### Ashok K Gupta (Corresponding Author)

Professor and Head, Department of Otolaryngology and Head and Neck Surgery, Postgraduate Institute of Medical Education and Research, Chandigarh, India, Phone: +919814198850, 0172-2756766 e-mail: drashokpgi@hotmail.com

### Bhumika Gupta

Senior Resident, Department of Otolaryngology and Head and Neck Surgery, Postgraduate Institute of Medical Education and Research Chandigarh, India

### Neha Gupta

Junior Resident, Department of Otolaryngology and Head and Neck Surgery, Postgraduate Institute of Medical Education and Research Chandigarh, India

### Nishikanta Tripathi

Junior Resident, Department of Otolaryngology and Head and Neck Surgery, Postgraduate Institute of Medical Education and Research Chandigarh, India