

Radiology Quiz

A 19-year-old male patient presented with history of nasal obstruction and nasal discharge for 6 months and swelling over dorsum of nose for 3 months.

On examination, there was a swelling over the dorsum of nose along with a polypoidal mass present in the nasal cavity (Fig. 1).

Radiology is as shown in the Figures 2 to 4.

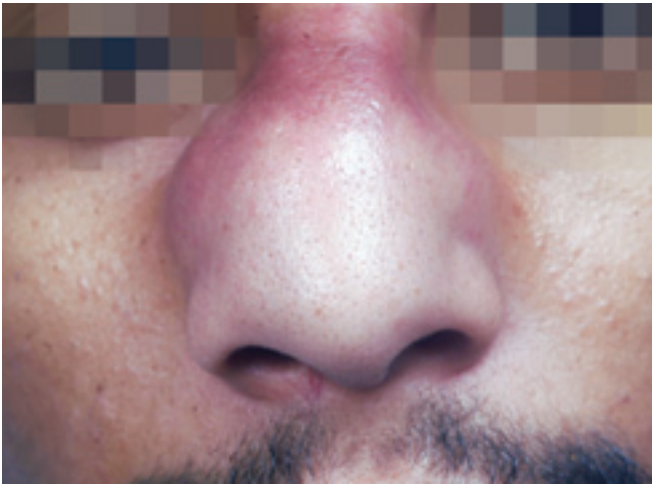

Fig. 1

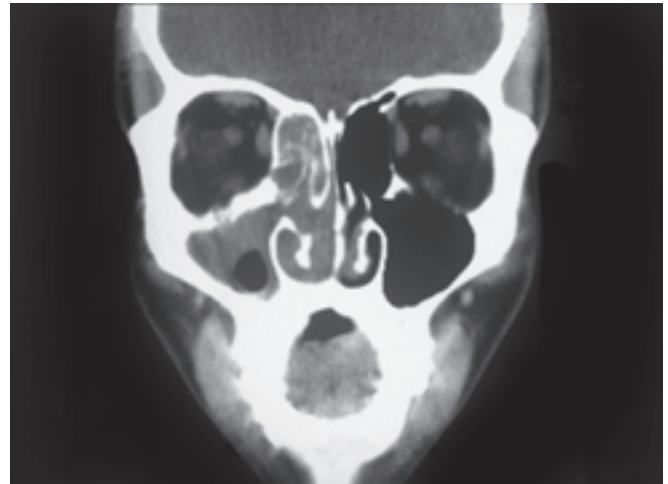


Fig. 3

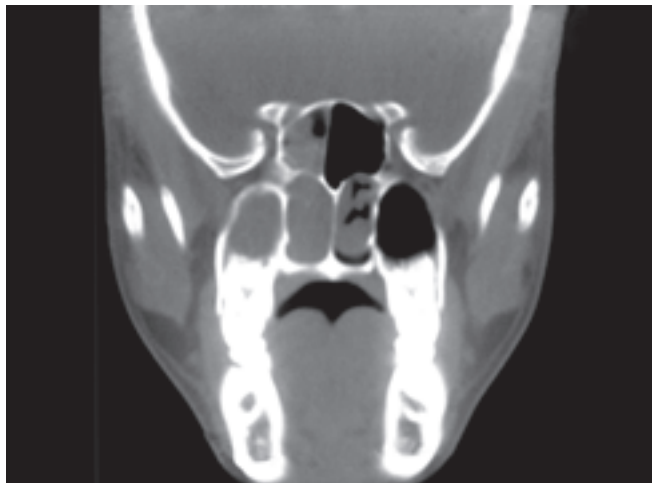

Fig. 2

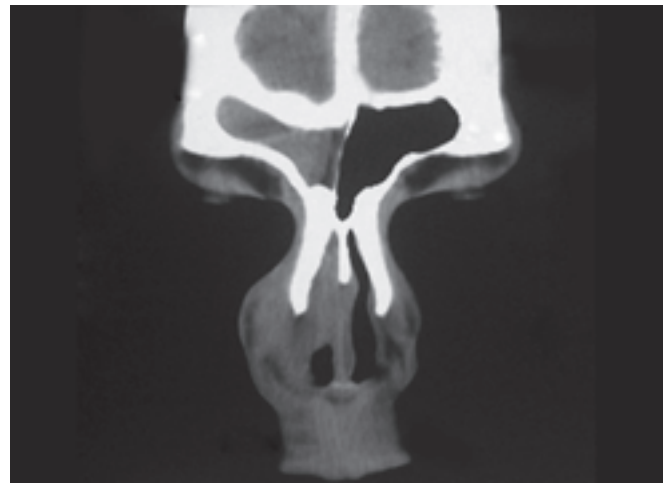


Fig. 4

The answer to the last quiz: Fibro-osseous lesion

Entries received : 36

Correct entries : 26

Send your diagnosis and comments on management to:

Editor-in-Chief

Room No. 25, Block D, Level 2

Faculty Office, Nehru Hospital

Postgraduate Institute of Medical Education and

Research, Chandigarh-160012, India

e-mail: drashokpgi@hotmail.com