

## Radiology Quiz

A 15-year-old female presented with complaint of forward protrusion of (L) eye  $\times$  4  $\times$  5 months which was gradually progressive and painless and was associated with decreased vision and diplopia with no nasal complaints.

On examination there was outward and lateral proptosis of (L) eye with vision  $>$  3 ft bilateral with normal extraocular movements with slight DNS towards (L) side (Fig. 1).

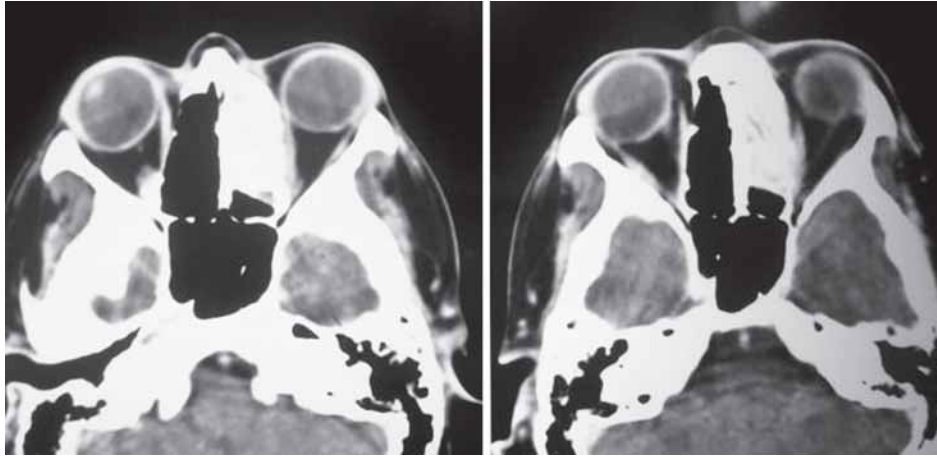


Fig. 1

CT scan nose and PNS orbit showed a calcified lesion in the area of left frontal sinus and ethmoid sinuses. The lesion was displacing left medial rectus muscle laterally with thinning of left lamina papyracea. A soft tissue density was also seen in left maxillary sinus (Figs 2 to 4).



Fig. 2

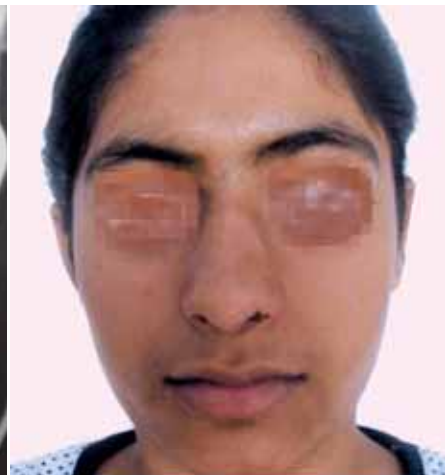

Fig. 3

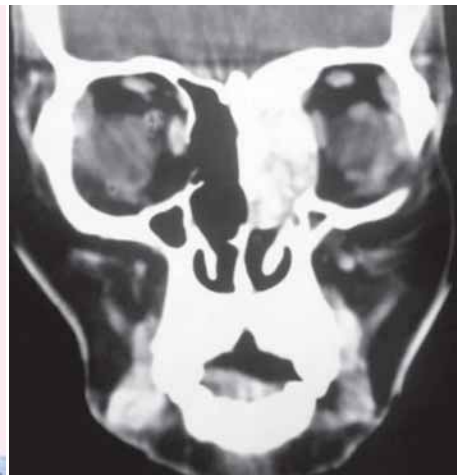

Fig. 4

*Send your diagnosis and comments on management to:*

**Editor-in-Chief**

Room No. 25, Block D, Level 2

Faculty Office, Nehru Hospital

Postgraduate Institute of Medical Education and

Research, Chandigarh-160012, India

e-mail: drashokpgi@hotmail.com

**The answer to the last quiz:** Aspergillosis

Entries received: 26

Correct entries: 4