

# Varied Ophthalmic Presentations in Sphenoid Sinus Lesions

<sup>1</sup>RG Aiyer, <sup>2</sup>Rahul Gupta, <sup>2</sup>Prarthna S Dhameja, <sup>3</sup>Virag Damania, <sup>4</sup>Abhishek Sharma, <sup>4</sup>Sumit Prinja

<sup>1</sup>Professor and Head, Department of ENT and Head and Neck Surgery, Government Medical College and SSG Hospital Vadodara, Gujarat, India

<sup>2</sup>Assistant Professor, Department of ENT and Head and Neck Surgery, Government Medical College and SSG Hospital Vadodara, Gujarat, India

<sup>3</sup>Senior Resident, Department of ENT and Head and Neck Surgery, Government Medical College and SSG Hospital Vadodara, Gujarat, India

<sup>4</sup>Junior Resident, Department of ENT and Head and Neck Surgery, Government Medical College and SSG Hospital Vadodara, Gujarat, India

**Correspondence:** Rahul Gupta, Assistant Professor, Department of ENT and Head and Neck Surgery, B-22, Ashalata Park Kamlanagar, Ajwa Road, Vadodara-390019, Gujarat, India, e-mail: doctor.rahul25@gmail.com, doc\_rahul25@yahoo.co.in

## ABSTRACT

Sphenoid sinus lesions can present with a multitude of symptoms/signs including ophthalmic disturbances.

We describe a total of five patients, of which two had mucocoeles and rest three had fungal infection. Ophthalmic symptoms/signs were the ones we were really interested in. We also present one case which had isolated sphenoid fungal sinus. We also give details of their presentation, investigations and treatment. Possible ocular manifestations of mucocoeles and the diagnostic imaging techniques used are discussed. The treatment of mucocoeles is reviewed. It is stressed that a team approach involving the ophthalmologist, otolaryngologist and radiologist is essential for accurate diagnosis and management.

**Keywords:** Endoscopic sinus surgery, Paranasal sinus, Mucocoele, Sphenoid sinus, Computed tomography, Magnetic resonance imaging.

## INTRODUCTION

The sphenoid sinus is the most deeply located of all the paranasal sinuses, lying directly beneath the sella turcica. Sphenoid sinus is closely related to 13 vital structures resulting in wide range of signs and symptoms due to their involvement.<sup>1</sup> Laterally lies the cavernous sinus; anteriorly the posterior wall of ethmoidal sinuses and posteriorly the brainstem.

The sphenoid sinus is also intimately related to the optic nerves, which may form a prominence on the lateral wall of sinus. Such close relationship places this important structure in jeopardy when the sphenoid sinus is diseased, and necessitate early diagnosis and intervention.

Sphenoid sinus lesions are not uncommon but are often difficult to diagnose, the presenting symptoms being vague and nonspecific.<sup>2</sup> Differential diagnosis for diseases of sphenoid sinus includes inflammatory lesions, primary benign neoplastic lesions, primary malignant neoplastic lesions, tumors invading from surrounding structures, metastatic carcinoma, aneurysms of ICA, ophthalmologic migraine and systemic diseases.<sup>3</sup> Ophthalmic involvement is a common finding in advanced lesions.

Computerized tomography (CT) and magnetic resonance imaging (MRI) are extremely useful in differential diagnosis of paranasal sinus lesions.<sup>4</sup> Radiological evaluation is also

useful in diagnosis of mucocoeles and help to explain the clinical symptoms by showing the spread of the lesion.<sup>5</sup>

## PATIENTS AND PRESENTATIONS

In this case series, we present five cases with sphenoid sinus lesions having varying degrees of ophthalmic involvement. In order to illustrate the great diversity of clinical signs, each case is individually presented. The characteristic radiological signs and the clinical management of individual cases are also presented.

### Case 1

A middle aged male patient with uncontrolled NIDDM presented to the physician in our hospital with complaint of headache (more on the left side) and occasional unsteadiness of gait. The patient also had ptosis and external ophthalmoplegia of left eye. With no obvious cause found, the treating physicians got a plain CT of head (only limited axial cuts) done. It showed opacified right sphenoid sinus. Rest of the scan did not show any abnormality. Only then was an otolaryngological opinion sought. With all the clinical factors and the limited radiological work-up pointing towards a fungal lesion, the patient was posted for endoscopic surgery under general anesthesia. Physicians put

the patient on insulin and doses were adjusted to obtain optimal glycemic control. Meanwhile, during the period of preparation, patient was put on high dose of 3rd generation cephalosporins. On seeking an ophthalmologic opinion, the patient was found to have diabetic retinopathy along with III cranial nerve palsy. Endoscopic examination revealed fungal debris in the sphenoid. A wide sphenoidotomy was performed and all the fungus was suctioned out. A thorough saline wash was given. Oral fluconazole was started in the postoperative period. Injectable antibiotics were continued for five postoperative days. Regular irrigations and suctioning of the opened sinus was carried out. The patient's ptosis improved dramatically with a gradual reduction in ophthalmoplegia. He was discharged on oral antibiotics, hypoglycemics, decongestants and advised of saline douching. The patient is on regular weekly follow-ups and is symptom free except for a minimal diplopia on right downward gaze (Figs 1 and 2).



Fig. 1: Preoperative and postoperative photographs of patients showing improvement in ptosis

## Case 2

A 27-year-old female with not known immunocompromised state presented with complaints of recurrent nasal obstructions. No ophthalmic complaints were present. Diagnostic endoscopy revealed extensive ethmoidal polypi. She had undergone multiple surgeries through transnasal endoscopic and Caldwell-Luc approaches in the preceding 2 to 3 years, for the same complaint. Even after being put on topical steroid sprays, her complaints recurred frequently. CT scan showed polypoidal mucosal thickenings involving all the paranasal sinuses on both sides besides obscuring the nasal cavities and nasopharynx.

The polypi were microdebrided and ethmoidectomies were performed on both sides. Sphenoid sinuses were found to have extensive fungal debris, which was confirmed on postoperative slide review. The patient was put on oral antifungals and topical steroids. She is on regular fortnightly follow-up and symptom free till this time (Figs 3 and 4).



Fig. 3: Young female having no ophthalmic involvement

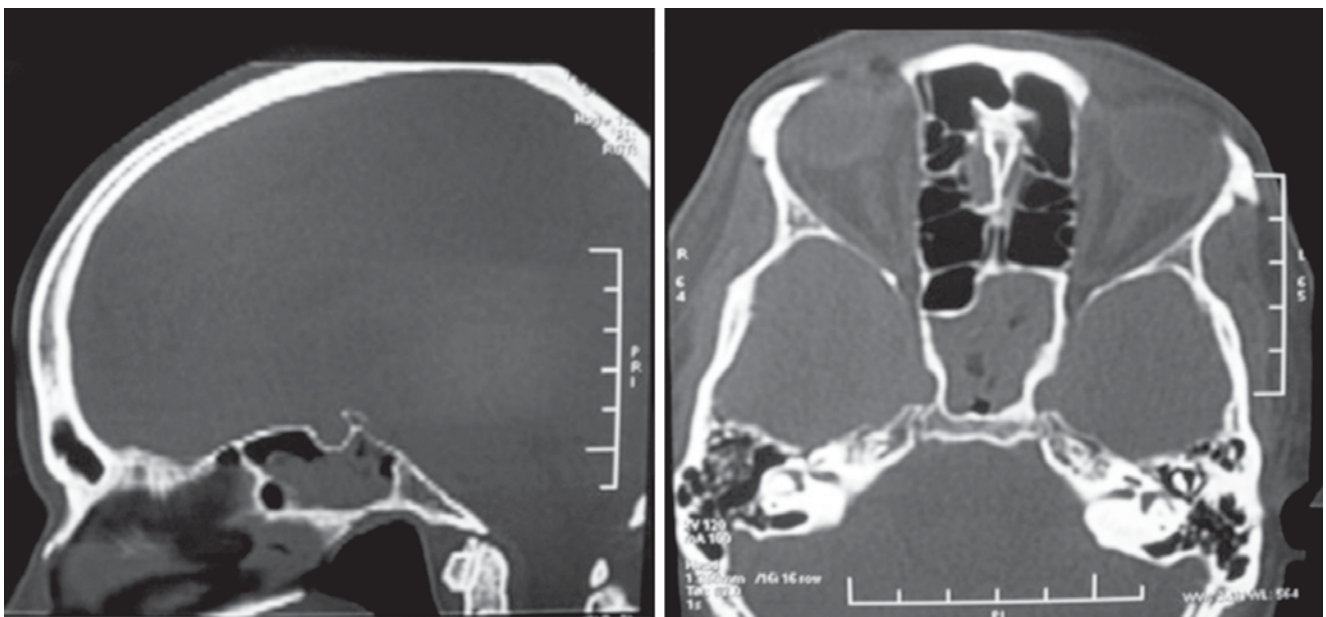
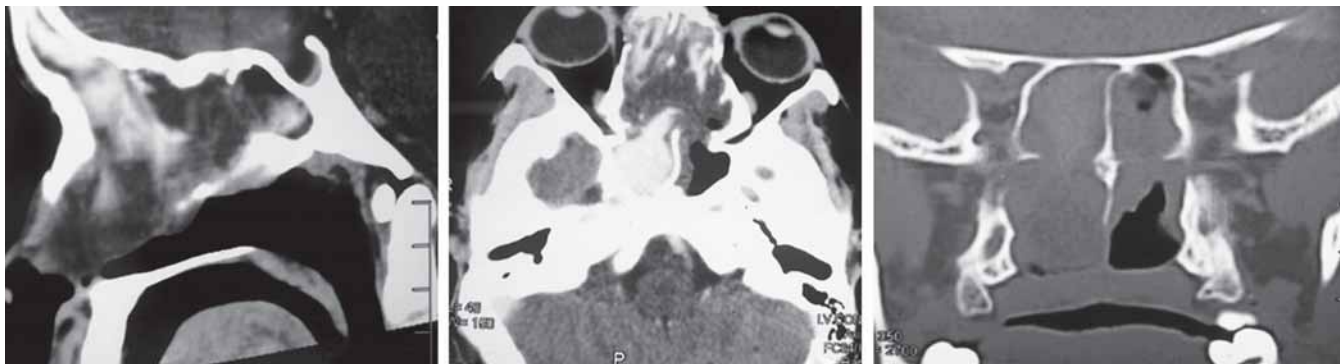


Fig. 2: CT scan showing soft tissue in sphenoid sinus



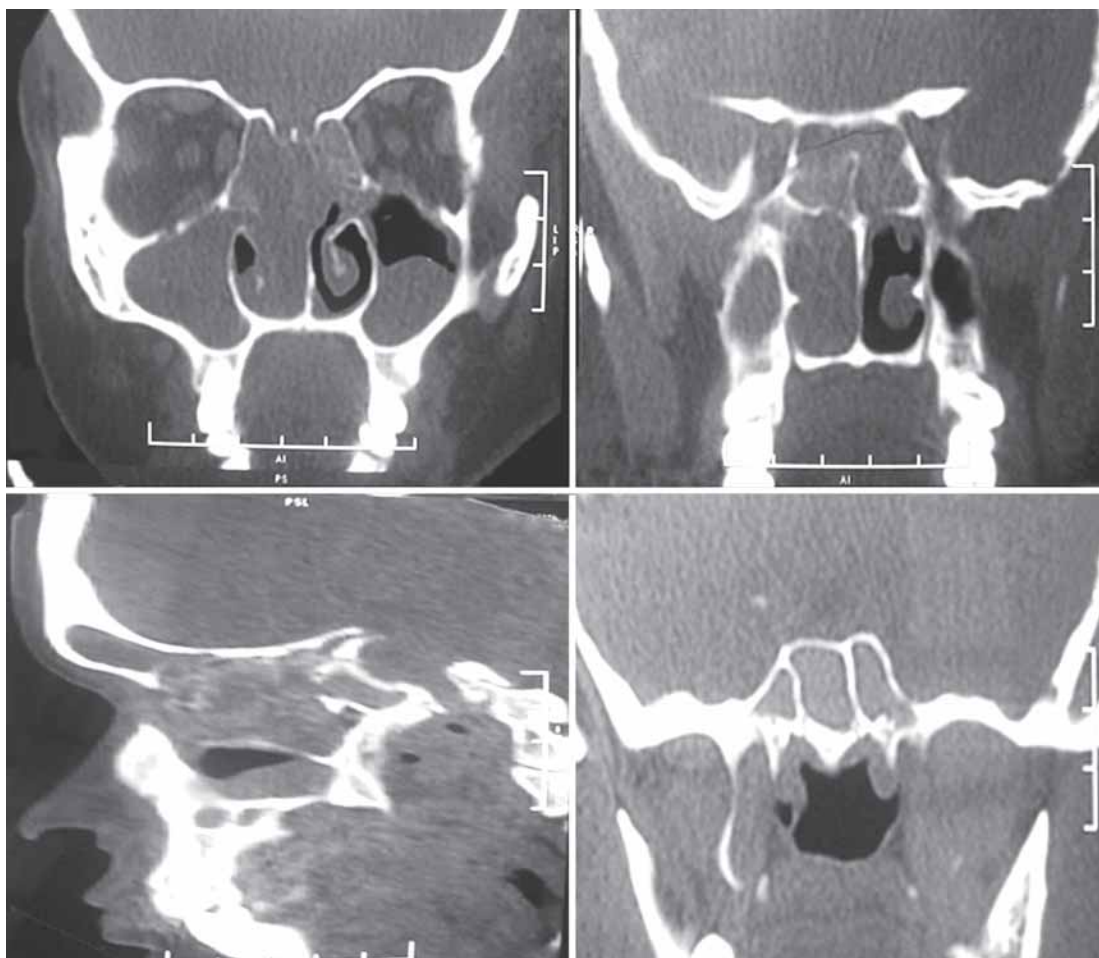
**Fig. 4:** Extensive bilateral paranasal sinus involvement

### Case 3

A 46-year-old hypertensive female presented with complaints of nasal obstruction and headache of a month long duration. CT scan showed an almost complete opacification of all the paranasal sinuses. There was no ophthalmic involvement, even though both the sphenoids were completely opacified. The patient was started on injectable antibiotics preoperatively and endoscopic clearance of all paranasal sinuses was done under general anesthesia. Postoperatively patient was put on topical steroids with almost complete resolution of symptoms (Fig. 5).

### Case 4

A 50-year-old countryside female with complaints of acute onset (1 month) vision loss, right eye ptosis, nasal discharge, and intermittent headache presented to the ophthalmologist at a private hospital. He found the patient to be having choroidal atrophy with optic atrophy (Fig. 6). There was no perception of light although the eyeball movements were normal. Suspecting it to be due to higher center involvement, the ophthalmologist advised for a brain MRI. The MRI demonstrated expansion of sphenoid sinus with large encapsulated collection within (hypointense on T1W and



**Fig. 5:** Complete opacification of both sphenoid sinuses presenting without any ophthalmic involvement

hyperintense on T2W). The lesion extended anteriorly into the ethmoid air cells and was encroaching bilateral optic canals with compression of both optic nerves. The lesion was also displacing the sella, pituitary gland and optic chiasma superiorly. It was displacing and stretching the right ICA along its margins. Changes of retro-obstructive sinusitis were also noted on the right side. About a week later, when the patient was referred to us, she was immediately posted for drainage of these obviously infected mucocoeles. Obvious immunocompromised states were ruled out beforehand. Prolapsing mucocoeles between the septum and middle turbinate were incised and copious pus was drained. Sphenoid sinus opening was further widened only to find a dehiscent ICA and optic nerve. Intersphenoid sinus septum was perforated, and hence both sinuses were connected. After giving a good betadine saline wash, ethmoidal cells were also cleared on the other side. Regular ophthalmological examinations in the postoperative period revealed minimal improvement in the lid lag but light could still not be perceived by the patient. Marcus Gunn pupil response was present on the right side. Eyeball movements were normal on both sides. Postoperatively patient was put on injectable Dexamethasone and Cefotaxime. Regular suction cleanings were performed. Patient was discharged on the tenth postoperative day with no improvement in vision and advised for regular follow-ups.

### Case 5

A 12-year-old female who was residing at Jodhpur, Rajasthan presented to us with complaint of swelling around left eye and protrusion of left eye for one month (Fig. 7). Patient had a saddle nose and a bulge was present in the superior wall of nasal cavity with mucopus present on the left side. Patient was admitted at a tertiary care center in northwest India where she was diagnosed as having pan sinusitis with orbital cellulitis on CT scan (Fig. 8). There

was expansion of left ethmoidal sinus associated with remodeling. Thick collections were seen in the left ethmoidal, left maxillary sinuses suggestive of mucopyocele. Inflammatory process was seen extending into orbit through medial wall (lamina papyracea) causing mild lifting of periosteum. There was a subperiosteal abscess involving superior rectus muscle. Left medial rectus was edematous with mild stranding of adjacent fat planes. Lesion was mainly confined to extracanal compartment of left orbit with proptosis of left eyeball. Right side orbit appeared grossly normal. Small ethmoidal mucocoele was also noted towards right side. It involved LPS muscle and superior rectus muscle. Small mucocoele also noted involving right ethmoid. Rest of the intraorbital muscles appeared normal. Both optic nerves, right orbit, both cavernous sinuses and right maxillary sinus were normal. Diagnostic nasal endoscopy done under LA showed pus and crusts that were removed from both nasal cavities. Maxillary antrum opening was widened and ostea decongested. Endoscopic excision/enucleation of mucopyocele of both side of paranasal sinuses was done under general anesthesia. Patient remained on regular follow-up till the fourth postoperative month and regular suction cleanings were performed.

### DISCUSSION

Sphenoid sinus lesions are very commonly complicated by ophthalmic involvement. Isolated sphenoid sinus disease is not very common and isolated fungal diseases of the sphenoid sinus are even less frequent.<sup>2</sup> Because of its rarity, its true incidence is difficult to establish, but it lies within the range of 2.7 to 8% based on larger series.<sup>6-8</sup> Diagnostically, sphenoid sinus represents a challenge as it does not present in a similar way to inflammation of the other paranasal sinuses, presenting symptoms being generally nonspecific.<sup>9</sup> We are reporting one of these scarce cases of isolated fungal sinusitis in this series (Case 1). Fungal

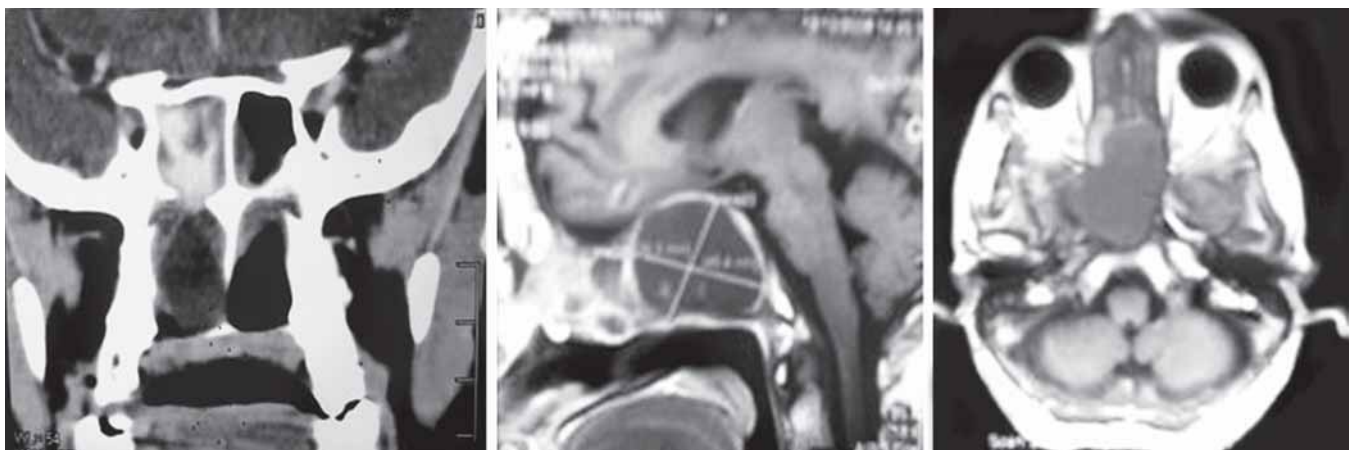
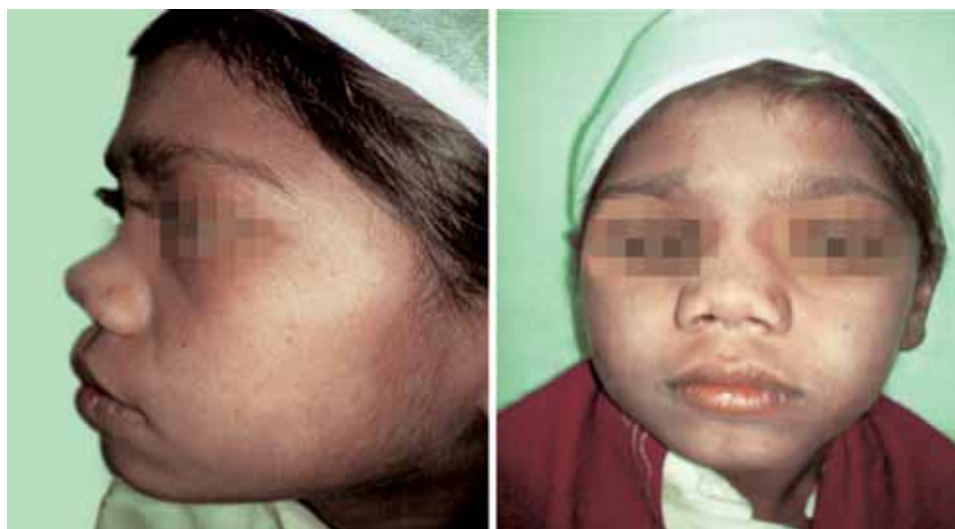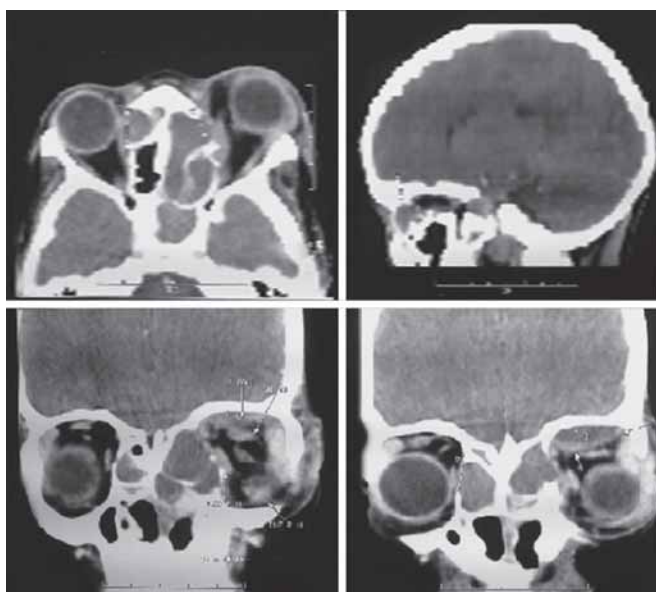


Fig. 6: Expansion of sphenoid sinus with large encapsulated collection within (hypointense on T1W and hyperintense on T2W)



**Fig. 7:** Young girl has saddling with mucopycocele of left maxillary, ethmoid and sphenoid sinuses



**Fig. 8:** Left paranasal sinus involvement with orbital cellulitis

sinusitis is most often associated with immunocompromised states particularly diabetic patients or those on long-term steroids. Isolated involvement of sphenoid sinuses by mucocoeles is also not so widespread. As the diagnosis is often delayed, the vital structures in and around the sphenoid may become affected and patients will often present with bizarre neurological complications as the first manifestation of their disease. In the absence of nasal symptoms, a high degree of suspicion is required to lead to the diagnosis of sphenoid sinus involvement. The typical headache caused by isolated sphenoid sinus lesion is usually described as transient, intermittent, deep seated, localized or throbbing character, and aggravated by standing, walking, bending, or coughing, and often interferes with sleep because it tends to be worse in the night. It is interesting to note that most of the cases of isolated fungal disease of the sinuses have been

associated with hot dry climates, such as Sudan, Northern India and Saudi Arabia.<sup>2</sup>

In this series, Case 1 presented with an isolated partial III nerve palsy while Case 5 presented with an isolated VI nerve palsy. Headache and retro-orbital pain may also be prominent features as in Case 4. In our series, mucocoeles were more common culprits for ophthalmic involvement (Cases 4 and 5). Of the rest 3 cases with fungal involvement of the sphenoid sinuses only 1, i.e. Case 1, had some ophthalmic involvement in form of an isolated partial III nerve palsy.

In cases with mucocoeles, endoscopic drainage/excision/enucleation needs to be performed. All cases with evidence of fungus in the sinus need to be opened up widely for adequate removal of fungal debris. Regular cleaning of the sinuses/cavities need to be performed in the postoperative period in all cases. Patients with recurrent ethmoidal polyps need to be started on topical steroids for a long duration of time. Antifungal agents like fluconazole, which have been used in our patients, leads to a speedy recovery in overall signs and symptoms.

## CONCLUSION

The keys to diagnosis and prevention of serious complications are familiarity with presentation of sphenoid sinus lesions and a high degree of suspicion. A team approach involving the ophthalmologist, otolaryngologist and radiologist is essential for accurate diagnosis and management.

Mucocoeles are more likely to cause ophthalmic involvement as compared to fungal disease. Fungal sinusitis should always be a differential diagnosis in diabetic patients presenting with complaints of vague headache and ophthalmoplegia.

## REFERENCES

1. Rifai M, Kenawi B. Visual dysfunction: Abnormal sign of benign sphenoid-ethmoidal lesions. *J Laryng Otol* 1990;104:217-21.
2. Chi-kee Leslie Shaw, Michael McCleave, Peter John Wormald. Unusual presentations of isolated sphenoid fungal sinusitis. *The J Laryng Otol* May 2000;114:385-88.
3. Keat-Jin-Lee, Ken Yanagisawa. An obscure etiology for headache: Sphenoid sinus disease. *Yonsei Med J* 1988;29(3): 209-18.
4. Ishibashi T, Kikuchi S. Mucocoele like lesions of the sphenoid sinus with hypointense focus on T2 weighted MRI. *Neuroradiology* 2001;43:1108-11.
5. Akan H, Cihan B, Çelenk Ç. Sphenoid sinus mucocoele causing third nerve paralysis: CT and MR findings. *Dentomaxillofacial Rad* 2004;33:342-44.
6. Lew D, Southwick FS, Montgomery WW, Weber AL, Baker AS. Sphenoid sinusitis: A review of 30 cases. *N Engl J Med* 1983;10:1149-54.
7. Weisberger EC, Dedo HH. Cranial neuropathies in sinus disease. *Laryngoscope* 1977;87:357-63.
8. JYZ Li, Yong TY, Khoo E, Russ GR, Grove DI, Coates PTH, et al. Isolated sphenoid fungal sinusitis in a renal transplant recipient presenting with bilateral abducens nerve palsy. *Transplant Int* 2007;20:640-42.
9. Sethi DS. Isolated sphenoid lesions: Diagnosis and management. *Otolaryngol Head Neck Surg* 1999;120:730-36.