

# Capillary Hemangioma of the Maxillary Sinus: A Case Report and Review of Literature

<sup>1</sup>Surinder K Singhal, <sup>2</sup>Charanjit Singh, <sup>3</sup>Rajeev Kumar, <sup>4</sup>Harsh Mohan

<sup>1</sup>Associate Professor, Department of Otorhinolaryngology, Government Medical College and Hospital, Chandigarh, India

<sup>2</sup>Ex-Senior Resident, Department of Otorhinolaryngology, Government Medical College and Hospital, Chandigarh, India

<sup>3</sup>Senior Resident, Department of Otorhinolaryngology, Government Medical College and Hospital, Chandigarh, India

<sup>4</sup>Professor, Department of Otorhinolaryngology and Pathology, Government Medical College and Hospital, Chandigarh, India

**Correspondence:** Surinder K Singhal, Associate Professor, Department of Otorhinolaryngology, Government Medical College and Hospital, Chandigarh, India, e-mail: singhalsks@yahoo.com

## Abstract

Capillary hemangioma of the maxillary sinus is a rare entity. It commonly presents as a sinonasal mass with nasal obstruction, intermittent epistaxis and occasionally as a cheek swelling. Computed tomography and angiography assist in making a correct diagnosis. Biopsy is not usually recommended as it can cause profuse bleeding and may yield false results. Selective arterial embolization followed by surgical resection forms the mainstay of treatment.

**Keywords:** Hemangiomas, maxillary sinus.

## INTRODUCTION

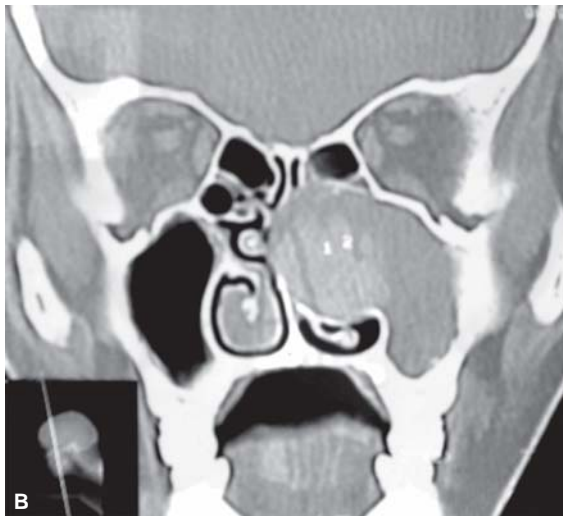
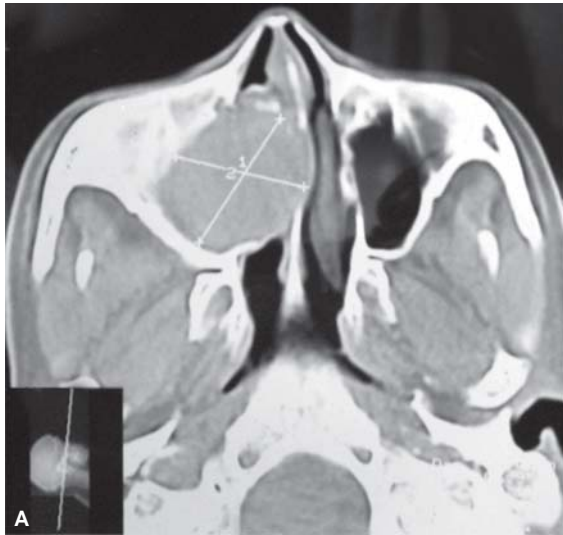Hemangiomas are benign vascular neoplasm that can occur in nearly every tissue in the human body. Although common in the head and neck region, they occur rarely in the paranasal sinuses.<sup>1</sup> Fu and Perzin<sup>2</sup> described only five cases of cavernous hemangiomas out of 85 vascular tumors involving the nasal cavity, paranasal sinuses and nasopharynx, none of them located in the maxillary sinus. However, hemangiomas of the maxillary sinus need to be considered in the differential diagnosis of a sinonasal mass since surgery or even biopsy can lead to a sudden loss of large quantities of blood.<sup>3</sup>

In the sinonasal tract, capillary hemangioma, cavernous hemangioma and angiomatosis are examples of hemangiomatous lesions. The overwhelming majority of sinonasal hemangiomas are of capillary type, whereas angiomatosis, i.e. a diffuse spread of thin-walled vessels accompanied by fat cells, and cavernous hemangiomas are extremely rare in the sinonasal tract.<sup>4</sup> Most of the sinonasal hemangiomas are located on the anterior part of the nasal septum and are of capillary type, whereas hemangiomas arising from the turbinates are often cavernous and grow in a lateral direction.<sup>5</sup> They grow slowly and can erode adjacent bones, making it difficult to differentiate them from the more common malignant epithelial tumors on the basis of radiology.<sup>5-8</sup>

A search of the database at PubMed yielded only 36 case reports of maxillary sinus hemangiomas published between 1962 and 2008. Data gathered from these articles was reviewed and has been presented along with a case report of a hemangioma arising from the maxillary sinus, eroding the medial wall of the maxillary sinus and causing significant widening of the osteomeatal complex.

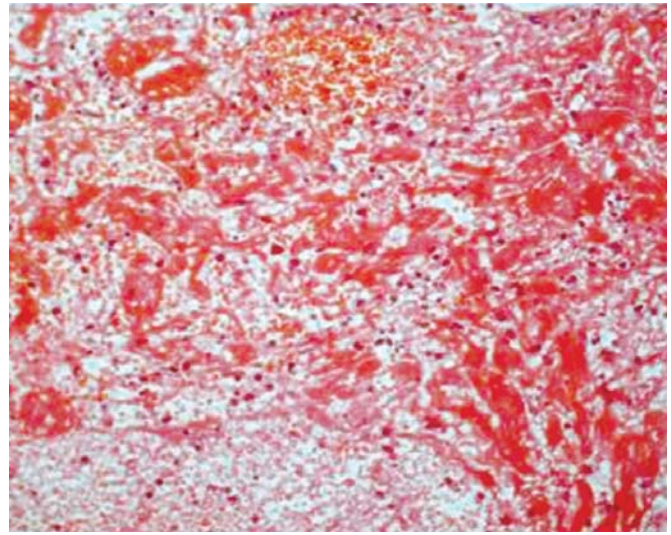
## CASE REPORT

A 35-year-old housewife presented with history of right sided nasal obstruction for last four years. It was insidious in onset, gradually progressive and was associated with intermittent mild epistaxis and postnasal discharge. There was no history of trauma, excessive sneezing, rhinorrhea, headache, decrease vision, double vision, toothache, pain or hemianesthesia of face, loosening of teeth, fever, anorexia and weight loss. Examination revealed a pinkish congested polypoidal mass in the right nasal cavity arising in the region of middle meatus and impinging on the nasal septum. NCCT scan revealed a soft tissue density mass lesion filling the right maxillary sinus and causing the widening of maxillary ostium, extending into the anterior ethmoidal air cells and the right nasal cavity and encroaching on the nasal septum. There was no intraorbital or intracranial extension. Sphenoid sinus was free of the mass lesion (Figs 1A and B).



**Figs 1A and B:** CT scan of the paranasal sinuses showing the tumor extent and destruction of the medial wall of right maxillary sinus

A provisional diagnosis of an infected antrochoanal polyp was made based on history and CT scan and a surgery under local anesthesia was planned. Nasal endoscopy revealed a pinkish congested polypoidal mass in the right middle meatus region which was arising from the right maxillary sinus and extending into the nasal cavity, pushing the middle turbinate and the nasal septum towards left. The mass was removed in toto using endoscopic approach and sent for histopathology. On table palpation of the mass lesion was soft-firm and was different from the usual antrochoanal polyp consistency. Histopathology revealed lobules of capillary sized vascular channels lined by endothelium and containing blood (Fig. 2). There were areas of organized hemorrhage with central collagen surrounded peripherally by hemosiderin laden macrophages. These findings were



**Fig. 2:** Photograph showing (H&E stain 100 x) cavernous spaces containing blood lined by endothelial cell

consistent with a capillary hemangioma. Patient was asymptomatic at 6 months' follow-up.

## DISCUSSION

A hemangioma of the maxillary sinus is a rare lesion with a variable and atypical radiographic appearance. Osseous cavernous hemangiomas in this anatomic location are quite rare,<sup>9</sup> but nonosseous hemangiomas originating from the mucosa of the sinonasal cavity are even more exotic lesions.<sup>2</sup> It may be difficult to distinguish hemangiomas of the sinonasal tract from vascular malformations and hamartomas as these conditions often mimic clinically. Hyams<sup>10</sup> emphasized the possibility of an erroneous diagnosis when a pyogenic granuloma is mistaken for a true hemangioma. More frequently, the maxilla wall becomes involved with a soft tissue hemangioma of the face or a vascular malformation of the skull. In our case, the tumor clearly originated from the mucosa of maxillary antrum.

There is considerable confusion in the nomenclature of vascular anomalies. Whereas clinicians usually employ Mulliken and Glowacki's classification<sup>11</sup> based on the clinical behavior and cellular kinetics, in which vascular anomalies are divided into two groups: hemangiomas and vascular malformations, pathologists classify these lesions descriptively on the basis of their histological characteristics and by the vessel type.<sup>12</sup> Naraghi et al<sup>13</sup> have reviewed the current and old classifications of vascular anomalies and described in detail the distinguishing features of true hemangiomas and vascular anomalies.

Pathogenesis of hemangiomas is poorly understood. It evolves with rapid proliferation involving pericyte and

endothelial cell hyperplasia and then enters a steady regression phase.<sup>14</sup>

## CLINICAL FEATURES

The clinical features, management and prognosis of various hemangiomas vary according to their location. For example, the skin and the oral mucosal hemangiomas have similar features; they are the most frequent hemangiomas and normally belong to the capillary group. They appear in the newborn or shortly after birth, have a good prognosis and usually disappear by the age of seven, thus no more than two percent of them require therapy. By contrast, hemangiomas in other parts of the head and neck are comparatively rare and show different behavior.

According to the literature, hemangiomas of the maxillary sinus can present over a wide age range varying from 9 to 78 years. However, most of the patients present in the 4th decade of life. There is no sex predilection. Although it commonly presents with nasal obstruction, epistaxis or a cheek swelling, there are reports of hemi facial pain,<sup>5</sup> headache,<sup>15</sup> discomfort of upper teeth,<sup>16</sup> epiphora<sup>13</sup> and earache.<sup>16</sup> It can also present as an incidental finding on radiology.<sup>17</sup> Examination commonly reveals a pinkish mass in the nasal cavity along with a cheek swelling. There can also be a fullness of canine fossa,<sup>18</sup> proptosis,<sup>18</sup> loose upper teeth<sup>19</sup> or a mass of the upper alveolus.<sup>20</sup> Due to rare involvement of the maxillary sinus, the differential diagnosis must include neuroma, mucocoeles, polypoid or cystic masses or other benign or malignant vascular tumors.<sup>3</sup>

Histologically, maxillary sinus hemangiomas have been most commonly reported as cavernous type,<sup>8,16,18,20</sup> however, capillary,<sup>15</sup> pleomorphic<sup>5</sup> and epitheloid<sup>6</sup> type of hemangiomas may also present in the maxillary sinus. Organized hematomas<sup>8</sup> or phleboliths<sup>15</sup> may lie within the stroma of the tumor.

## RADIOLOGY

Appropriate preoperative imaging studies are mandatory to establish the correct diagnosis. A contrast enhanced CT scan is the investigation of choice in most cases and it usually demonstrates a nonhomogenously enhancing lesion in the maxillary sinus.<sup>7</sup> These lesions can cause substantial bone erosion,<sup>5-8</sup> the appearance of which can mislead the radiologist to the false diagnosis of a malignant tumor. This kind of bone erosion can also occur with other benign lesions such as inverted papillomas or sinonasal polyps. A gadolinium enhanced MRI may show a hyper intense signal on T2-weighted images and can help in reaching the

diagnosis. Angiography is always warranted if there is any suspicion about the nature of these lesions as it can clearly demonstrate the location, extent and feeders to the tumor and show whether it communicates intracranially, thus providing valuable information for planning the mode of treatment.<sup>21</sup>

## TREATMENT

Treatment usually requires a complete excision by either a lateral rhinotomy,<sup>5,13</sup> Caldwell-luc,<sup>15,19</sup> Weber-Fergusson<sup>18</sup> or an endoscopic<sup>16,17,22</sup> approach. The surgical approach should be chosen after radiological assessment of the extent of the lesion and vascular supply keeping in mind that profuse bleeding must be expected, and an unrestricted field of view is advisable in order to control the hemorrhage. Preoperative embolization should be seriously considered as an adjunct to surgical resection as it considerably reduces the amount of intraoperative bleeding.<sup>19,22</sup> Laser excision and steroids have been advocated as alternative treatments for hemangiomas at other sites in the head and neck; however, these treatment modalities have not reportedly been used for hemangiomas of the sinonasal tract.

## CONCLUSION

Hemangiomas of the paranasal sinuses are rare. A high index of suspicion is needed to diagnose these cases in early stages when it is limited to a particular sinus with clinical features mimicking the more common sinonasal pathology like antrochoanal polyp. CT scan and angiography can clinch the diagnosis in these suspicious cases. Surgical excision of the lesion is the treatment of choice. Preoperative embolization is useful in extensive lesions.

## REFERENCES

1. Batsakis JG. Tumors of the Head and Neck: Clinical and Pathological Considerations. Baltimore: Williams & Wilkins, 1979;291-312.
2. Fu YS, Perzin KH. Nonepithelial tumours of the nasal cavity, paranasal sinuses and nasopharynx: A clinicopathologic study. *Cancer* 1974;33:1275-88.
3. Engels T, Schorner W, Felix R, Witt H, Jahnke V. Kavernöses Hämangiom des Sinus maxillaris. *HNO* 1990;38(9):342-44.
4. Hellquist HB. Pathology of the nose and paranasal sinuses. Butterworth and Co. Ltd., London, 1990;136-42.
5. Raboso E, Rosell A, Plaza G, Martinez-Vidal A. Haemangioma of the maxillary sinus. *J Laryngol Otol* 1997;111:638-40.
6. Kurihara K, Saiki T, Takeda K, Kobayashi J. Epitheloid hemangioma of the maxillary sinus: A case report. *J Oral Maxillofac Surg* 1995;53(10):1221-23.
7. Kim HJ, Kim JH, Hwang EG. Bone erosion caused by sinonasal cavernous hemangioma: CT findings in two patients. *Am J Neuroradiol* 1995;16(5):1176-78.

8. Jammal H, Barkat F, Hadi U. Maxillary sinus cavernous hemangioma: A rare entity. *Acta Otolaryngol* 2004;124(3): 331-33.
9. Mc Allister RM, Ruddy GN, Hancock K, Sanders R. Cavernous hemangioma of the nasal bones. *J Laryngol Otol* 1992;106(3):264-67.
10. Hyams VJ. Pathology of the Nose and Paranasal Sinuses. In English GM (Eds): *Otolaryngology*, New York, Harper and Row, Publishers, Inc, 1984;2.
11. Mulliken JB, Glowacki J. Hemangiomas and vascular malformations in infants and children: A classification based on endothelial characteristics. *Plast Reconstr Surg* 1982;69: 412-20.
12. Weiss SW, Goldblum JR. *Enzinger and Weiss's Soft Tissue Tumours* (4th ed). St Louis: Mosby, 2001.
13. Naraghi A, Keene M. Maxillary intraosseous vascular malformation: A case report and literature review. *J Laryngol Otol* 2007; 121(4):404-07.
14. Marchuk DA. Pathogenesis of hemangioma. *J Clin Invest* 2001;107(6):665-66.
15. Most DS. Hemangioma of the maxillary sinus. *Oral Surg Oral Med Oral Pathol* 1985;60:485-86.
16. Mussak E, Lin J, Prasad M. Cavernous hemangioma of the maxillary sinus with bone erosion. *Ear Nose Throat J* 2007;86:565-66.
17. Kulkarni MV, Bonner FM, Abdo GJ. *J Comput Assist Tomogr* 1989;13(2):340-42.
18. Ghosh LM, Samanta A, Nandy T, Das S. Hemangiomas of the maxilla. *J Laryngol Otol* 1988;102:725-26.
19. Cansiz H, Yener M, Kalekoclu N, Dalkilic O. Arteriovenous malformation of the maxillary sinus and mandible: A case report. *Ear Nose Throat J* 2003;82(8):608-14.
20. Yasuoka T, Okumura Y, Okuda T, Oka N. Hemangioma and hemangioendothelioma of the maxillary sinus. *J Oral Maxillofac Surg* 1990;48:877-81.
21. Shira RB. Clinical application of angiography of oral and maxillofacial hemangiomas. *Oral Surg Oral Med Oral Pathol* 1983;55:437-47.
22. Kanazawa T, Inoue R, Ohta Y, Watanabe Y, Iino Y. Maxillary hemangioma successfully resected by endoscopic approach. *J Laryngol Otol* 2008 Jun 25:1-3 (Epub ahead of print).